

## Clinical results of femoral head fracture-dislocation treated according to the Pipkin classification

Xiao Yu<sup>1</sup>, Qing-Jiang Pang<sup>2</sup>, Xian-Jun Chen<sup>3</sup>

### ABSTRACT

**Objective:** To summarize the clinical results of femoral head fracture-dislocation treated according to Pipkin classification.

**Methods:** A total of 19 patients with femoral head fracture-dislocation were retrospectively analyzed from Mar. 2008 to Mar. 2015. According to the classification of Pipkin criteria, there were 4 cases in Type-I, 6 cases in Type-II, 6 cases in Type-III and 3 cases in Type-IV. Various procedures were taken according to the different types of the fracture, the time of the fracture, and the age of the patients. X-ray was examined during the follow-up period and functional evaluation was carried out by Harris Hip Score's criteria. The clinical therapeutic effects were analyzed.

**Results:** All the patients got a mean follow-up of 18 months (9-36 months). No patient suffered from infection, skin flap necrosis and X-ray showed no implants loosening or breakage. According to the Harris Hip Score's criteria, in Type-I, 4 cases were rated as excellent. In Type-II, 2 cases rated as excellent, 3 cases as good and 1 case as fair. In Type-III, 3 cases rated as good, 2 cases as fair and 1 case as poor. In Type-IV, 1 case rated as excellent, 1 case as good and 1 case as fair. The overall rate of excellent and good was 73.7%.

**Conclusions:** Pipkin classification is helpful to make preoperative plan and judging the prognosis in cases of femoral head fracture-dislocation. However, multiple factors such as the time from injury to surgery, the ages of patients, the selection of implants should also be considered, which may affect the clinical results.

**KEYWORDS:** Femoral head fracture-dislocation, Harris Hip Score's criteria, Pipkin classification.

doi: <https://doi.org/10.12669/pjms.333.12633>

### How to cite this:

Yu X, Pang QJ, Chen XJ. Clinical results of femoral head fracture-dislocation treated according to the Pipkin classification. *Pak J Med Sci.* 2017;33(3):650-653. doi: <https://doi.org/10.12669/pjms.333.12633>

This is an Open Access article distributed under the terms of the Creative Commons Attribution License (<http://creativecommons.org/licenses/by/3.0>), which permits unrestricted use, distribution, and reproduction in any medium, provided the original work is properly cited.

### INTRODUCTION

Femoral head fracture-dislocation, alternatively also called Pipkin fracture, is mostly caused by high energy injuries.<sup>1</sup> Because it is seldom seen in clinical

practice, the surgeons always focus on the femoral head dislocation and the minor fracture fragments from the femoral head can be easily missed.<sup>2</sup> The missed diagnosis of Pipkin fracture will cause poor prognosis unless the patient accepts the total hip arthroplasty (THA) on initial presentation since it can be easily cause late onset of femoral head necrosis and traumatic arthritis.<sup>3</sup> However, for the young patients, offering a primary replacement arthroplasty for traumatic fracture-dislocation maybe controversial. Therefore, the therapeutic requirements and difficulties of Pipkin fracture are high.

At present, the Pipkin classification is widely used in the femoral head fracture-dislocation<sup>4,5</sup> however, seldom has the literature linked a Pipkin fracture with preoperative plan and prognosis. In this study, we have retrospectively analyzed 19 patients' clinical results of femoral head fracture-dislocation.

1. Dr. Xiao Yu, PhD

2. Dr. Qing-Jiang Pang, PhD

3. Dr. Xian-Jun Chen, MD

1-3: Department of Orthopedics,  
Ningbo No.2 Hospital, Ningbo, 315010,  
Zhejiang, China.

#### Correspondence:

Dr. Qing-jiang Pang,  
Ningbo No.2 Hospital, Ningbo 315010,  
Zhejiang, China.

E-mail: [pqjey@sina.com](mailto:pqjey@sina.com)  
[yuxiao19@163.com](mailto:yuxiao19@163.com)

\* Received for Publication: February 28, 2017

\* Accepted for Publication: April 12, 2017

## METHODS

**Clinical data:** A total of the 19 patients (15 males and 4 females) of femoral head fracture-dislocation were treated from Mar. 2008 to Mar. 2015. The age ranged from 25 to 63 years old (40.2 years old in average). All the patients were diagnosed as unilateral femoral head injury. According to Pipkin classification, there were 4 cases in Type-I, 6 cases in Type-II, 6 cases in Type-III and 3 cases in Type-IV. Furthermore, 2 cases in Type-III were had a concomitant fracture of the superior and inferior ramus of the pubis on the same side. In one case, Type-IV had an injury of sciatic nerve.

**Treatment methods:** Conservative therapy of femoral supracondylar traction reduction was performed on 3 cases of Type-I and 1 case of Type-II. The other 15 cases were treated surgically. Pre-operative femoral supracondylar traction was carried out once the patients were hospitalized. Of all the 15 cases subjected to surgical treatment, the femoral head was reduced within 48 hours after the injury in 9 cases, 48 hours~1 week in 3 cases and 1 week~2 weeks in 3 cases. 1 case in Type-IV underwent emergent nerve exploration for the concomitant injury of the sciatic nerve. 3 cases in Type-IV underwent internal fixation by reconstruction plates for the acetabulum and absorbable screws for the femoral head respectively after the vital signs were stable. 1 case aged 63 in Type-III was treated with total hip arthroplasty, while the other 2 cases were treated with open reduction by cannulated screw fixation. The rest of the 3 cases with closed reduction by cannulated screw fixation leaving the femoral head fractures in non-weight bearing area untreated. The other cas-

es, whose fracture belonged to Type-I and Type-II were treated with open reduction and absorbable screws fixation. In the cases of open reduction and internal fixation, the Smith-Peterson approach was used in 4 cases while the Kocher-Langenbeck approaches in 7 cases.

**Postoperative management:** Postoperatively, femoral supracondylar traction was used to the cases treated with open or closed reduction and internal fixation for another 8 weeks. The patients were encouraged to do the quadriceps femoris rehabilitation exercise when as pain decreased.<sup>6</sup> However, the patient with THA was asked to walk full weight-bearing within 2 weeks postoperatively. X-ray examination was carried out once a month during the first 3 months then it could be taken at the 6<sup>th</sup> month and the 12<sup>th</sup> month to evaluate the efficacy of reduction maintenance and judge whether the femoral head necrosis occurred. Regular follow-up was maintained and the functional recovery was evaluated according to the Harris Hip Score's criteria when the patient can walk full weight-bearing.

## RESULTS

All the 19 patients were accepted followed-up for 9-36 months (18 months in average) and the postoperative complications such as infection, skin flap necrosis, loosening or breakage of the implants, nonunion or malunion were not detected. In every visit, pain, gait, range of the motion, weight-bearing of the joint were evaluated and the X-ray were taken. A note was made of joint space of the hip, the collapse of the femoral head, and the heterotopic ossification of the hip joint. According to Harris

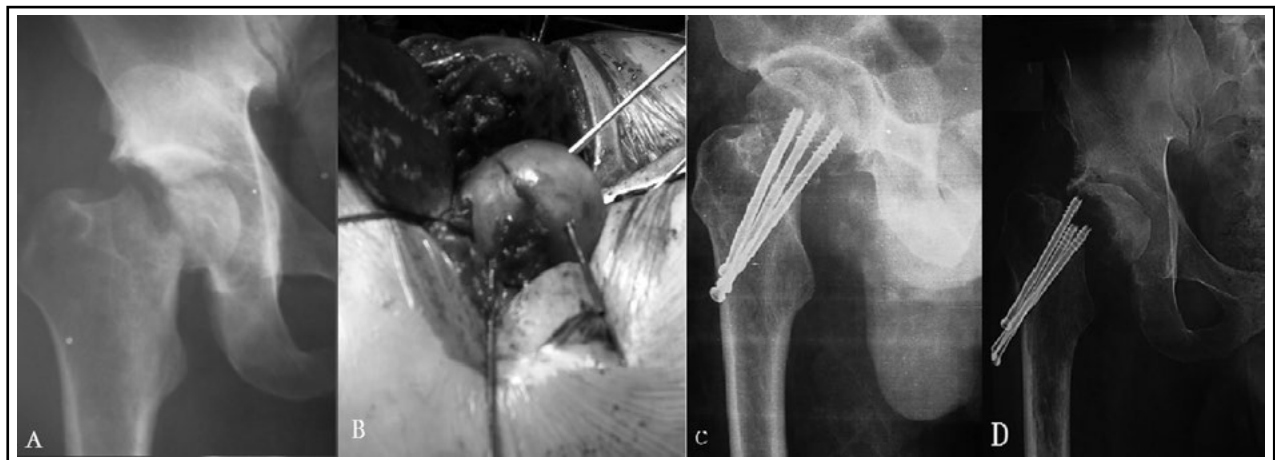


Fig.1: A male patient, with Type-III Pipkin fracture (A), In the initial surgery, the femoral head ligament was cut to reduce the femoral head fracture with cannulated screws. (B, C), In the 36<sup>th</sup> month follow-up, he suffered from pain and joint movement disorder with obvious collapse and necrosis of the femoral head showed on X-ray. The Harris Hip Score was rated as poor (D).

Hip Score's criteria, 4 case in Pipkin Type-I were rated as excellent; in Type-II, 2 cases were rated as excellent, 3 as good, and 2 as fair; in Type-III, 3 as good, 2 as fair and 1 as poor; and in Type-IV 1 as excellent, 1 as good and 1 as fair, the overall rate of excellent and good was 73.7%. The case scoring as poor in Type-III suffered from pain, with obvious collapse and necrosis of the femoral head showed on his X-ray in his 36<sup>th</sup> month follow-up (Fig.1).

## DISCUSSION

The types of Pipkin fracture depends on location and direction of force from femoral head to acetabulum. If flexion degree of hip joint is  $>60^\circ$  in the moment of trauma, Type I or II Pipkin fracture could occur. However, if flexion degree is  $<60^\circ$ , it could result in Type III or IV fracture.<sup>7</sup> Pipkin classification is significant in making preoperative plan and predicting prognosis.

The femoral head necrosis occurs due to lack of blood supply resulted from prolonged dislocation of the hip joint and accelerates if the femoral head ligament is cut in operation to deteriorate the blood supply.<sup>8</sup> Traumatic arthritis may develop due to poor reduction of fracture in the weight bearing area of the articular surface. Therefore, the management aim is to restore the articular surface as soon as possible.<sup>6</sup> In this study, 9 cases was scheduled to operation within 48 hours. 2 cases of Type-III concomitant the fracture of the superior and inferior ramus of the pubis underwent operation 48 hours to a week. 3 cases of Type-IV were treated a week later for their seriously concomitant fracture of acetabulum. The results showed the cases treated earlier than 48 hours showed better outcome since the remaining blood supply of the femoral head may be better preserved if the reduction can be achieved early.

We achieved a satisfying overall result in 19 patients in their follow-up as mean rate of excellent and good in four types was 73.7%, especially in 3 cases of Type-IV. Therapeutic results were related to time of follow-up for femoral head necrosis and traumatic arthritis may not appear in a short time. In this study, the case accepted the operation a week later showed satisfying result according to the latest follow-up. We believed it was attributed to the femoral supracondylar traction, which was helpful to reduce the swelling of the soft tissue in the hip joint.

Choice of approach is controversial.<sup>9,10</sup> The approaches often used are anterior approach Smith-Petersen and posterior approach Kocher-Langenbeck.

The advocates of the posterior approach believe that most femoral head dislocation fall into the category of the posterior dislocation, in which the simultaneous posterior capsular laciniate usually occurred and the blood supply for the femoral head from the medial femoral circumflex artery would be destroyed. Therefore, if the anterior approach was used, it would destroy the left blood supply of femoral head because the ascending branch of lateral femoral circumflex artery and anterior capsular must be cut by this approach.<sup>11</sup> While some scholars believe that the posterior approach is difficult to expose, reduce and fix the fractures in the anterior, medial and inferior parts of femoral head unless the incision became longer.<sup>12</sup> It is advisable to choose anterior approach to expose, reduce and fix for Type-I or Type-II as the fracture was in the anterior and inferior of the femoral head. While for Type-III or Type-IV, the posterior approach is more convenient for reduction and fixation of posterior wall fracture of acetabulum.<sup>13</sup>

Anatomic reduction and effective fixation of femoral head fracture can reduce the traumatic arthritis rate. It is advocated to surgical management as long as it is indicated. As for Type-I, the fracture could be removed if it is small in non-weight bearing area. However, as for fracture larger than 1/3 of joint surface, it should be preserved and treated with internal fixation. Open reduction should be done as early as possible in Type-II since the fracture is always large in weight bearing area.<sup>14</sup> The implants can be divided into metal screw and absorbable screw. The scholars who preferred absorbable screw believe that strength of absorbable screw is enough and the stress would be transferred to healing bone surface.<sup>15</sup> In this study, 11 cases were fixed by absorbable screws and showed satisfying clinical results. As for the cases of Type-III, the rate of femoral head necrosis will increase enormously for the destruction of blood supply of the femoral head by open reduction. Therefore, we believe that the indication for THA should be extensive in the cases of Type-III. In this study, the patient in Type-III were treated by THA and showed no claudication and pain in 12<sup>th</sup> month follow-up. As the fracture in Type-IV concomitant acetabulum fracture, it is difficult to maintain the state of reduction after traction, and cartilage degeneration and joint stiffness may occur if joint is fixed for a long time. Furthermore, the fracture of acetabulum should be fixed simultaneously with the reduction of femoral head in order to prevent malalignment between acetabulum and femoral head.<sup>16</sup>

The rate of sciatic nerve injury caused by Pipkin fracture was about 10% and approximately, 60%-70% of the sciatic nerve injury could recover.<sup>6</sup> In this study, 1 case accepted emergency nerve exploration for concomitant injury of sciatic nerve and we found that the femoral head in posterior dislocation lacerated the posterior capsular. Therefore, the sciatic nerve was in the state of distraction and entrapment. The rate of traumatic arthritis in femoral head fracture-dislocation is 24% and it will increase when concomitant acetabulum fracture, unanatomical reduction and delayed reduction.<sup>8</sup> The femoral head necrosis may be related to time from injury to surgery, original or iatrogenic injury of medial femoral circumflex artery. We believed that in order to avoid the femoral head necrosis in a maximum degree, the reduction operation should be taken as early as possible. In this study, 1 case of Type-III suffered from Pipkin fracture concomitant superior and inferior ramus of the pubis accepted open reduction and internal fixation after 48 hour later when the active bleeding was excluded. However, in the process of operation, the ligament of femoral head was cut to take out of the fracture bone then it was fixed to the femoral head with cannulated screw. Therefore, the blood supply of the femoral head was destroyed seriously. In the 36<sup>th</sup> month follow-up, pain and joint movement disorder with obvious collapse and necrosis of the femoral head appeared. Harris hip score was rated as poor.

#### ACKNOWLEDGEMENT

This study was supported by a grant from the Natural Science Foundation of Ningbo City (No. 2014A610250) and Rising Star in Medicine Project in Zhejiang Province (No.2015-70).

#### REFERENCES

- Schlummer T, Gude A. Hip dislocation and fracture of the femoral head caused by low impact trauma. *Unfallchirurg*. 2010;113(3):235-238. doi: 10.1007/s00113-009-1712-0.
- Uzel AP, Mazzola C, Lebreton G, Wilson G, Rouvillain JL. Hip subluxation associated with Pipkin II fracture: an injury to look for before reduction. *Chir Organi Mov*. 2009;93(1):33-35. doi: 10.1007/s12306-009-0021-7.
- Giannoudis PV, Kontakis G, Christoforakis Z, Akula M, Tosounidis T, Koutras C. Management, complications and clinical results of femoral head fractures. *Injury*. 2009;40(12):1245-1251. doi: 10.1016/j.injury.2009.10.024.
- Tripathy SK, Sen RK, Goyal T. Conservative versus surgical management of Pipkin type I fractures associated with posterior dislocation of the hip: A randomised controlled trial. *Int Orthop*. 2011;35(12):1907-1908. doi: 10.1007/s00264-011-1352-1.
- Mostafa MF, El-Adl W, El-Sayed MA. Operative treatment of displaced Pipkin Type-I and II femoral head fractures. *Arch Orthop Trauma Surg*. 2014;34(5):637-644. doi: 10.1007/s00402-014-1960-5.
- Tonetti J, Ruatti S, Lafontan V, Loubignac F, Chiron P, Sari-Ali H, et al. Is femoral head fracture-dislocation management improvable: A retrospective study in 110 cases. *Orthop Traumatol Surg Res*. 2010;96(6):623-631. doi: 10.1016/j.otsr.2010.03.020.
- Kokubo Y, Uchida K, Takeno K, Yayama T, Miyazaki T, Negoro K, et al. Dislocated intra-articular femoral head fracture associated with fracture-dislocation of the hip and acetabulum: report of 12 cases and technical notes on surgical intervention. *Eur J Orthop Surg Traumatol*. 2013;23(5):557-564. doi: 10.1007/s00590-012-1027-7.
- Lazaro LE, Sculco PK, Pardee NC, Klinger CE, Dyke JP, Helfet DL, et al. Assessment of femoral head and head-neck junction perfusion following surgical hip dislocation using gadolinium-enhanced magnetic resonance imaging: a cadaveric study. *J Bone Joint Surg Am*. 2013;95(23):e1821-e1828. doi: 10.2106/JBJS.L.01185.
- Uzel AP, Laflamme GY, Rouvillain JL. Irreducible Pipkin II femoral head fractures: Is transgluteal approach the best strategy? *Orthop Traumatol Surg Res*. 2010;96(6):695-701. doi: 10.1016/j.otsr.2010.04.011.
- Gavaskar AS, Tummala NC. Ganz Surgical Dislocation of the Hip Is a Safe Technique for Operative Treatment of Pipkin Fractures. Results of a Prospective Trial. *J Orthop Trauma*. 2015;29(12):544-548. doi: 10.1097/BOT.0000000000000399.
- Chen ZW, Zhai WL, Ding ZQ, Lian KJ, Kang LQ, Guo LX, et al. Operative versus nonoperative management of Pipkin type-II fractures associated with posterior hip dislocation. *Orthopedics*. 2011;34(5):350. doi: 10.3928/01477447-20110317-09.
- Müller DA, Zingg PO, Dora C. Anterior minimally invasive approach for total hip replacement: five-year survivorship and learning curve. *Hip Int*. 2014;24(3):277-283. doi: 10.5301/hipint.5000108.
- Thannheimer A, Gutsfeld P, Bühren V. Current therapy options for fractures of the femoral head. *Chirurg*. 2009;80(12):1140-1146. doi: 10.1007/s00104-009-1738-4.
- Lin D, Lian K, Chen Z, Wang L, Hao J, Zhang H. Emergent surgical reduction and fixation for Pipkin type I femoral fractures. *Orthopedics*. 2013;6(6):778-782. doi: 10.3928/01477447-20130523-24.
- Hermus JPI, Laan CA, Hogervorst M, Rhemrev SJ. Fixation of a Pipkin fracture with bioabsorbable screws. Case report and a review of the literature. *Injury*. 2005;36(3):458-461. doi: 10.1016/j.injury.2004.07.021.
- Li YL, Tang YY. Displaced acetabular fractures in the elderly: Results after open reduction and internal fixation. *Injury*. 2014; 45(12):1908-1913. doi: 10.1016/j.injury.2014.09.004.

#### Authors` Contributions:

**XY** designed the subject and did the manuscript writing and edited the final manuscript.

**QJP** did the operation.

**XJC** collected the clinical data followed up the patients.