



Comparing the Efficacy of Triclosan Coated Sutures versus Chlorhexidine Coated Sutures in Preventing Surgical Site Infection after Removal of Impacted Mandibular Third Molar

Sneha Krishnan¹, Senthilnathan Periasamy^{1*} and Arun Murugaiyan¹

¹*Department of Oral and Maxillofacial Surgery, Saveetha Dental College and Hospital, Saveetha Institute of Medical and Technical Science, Saveetha University, Chennai 77, India.*

Authors' contributions

This work was carried out in collaboration among all authors. Author SK designed the study, performed the statistical analysis, wrote the protocol and wrote the first draft of the manuscript. Authors SP and AM managed the analyses of the study. Author AM managed the literature searches. All authors read and approved the final manuscript.

Article Information

DOI: 10.9734/JPRI/2020/v32i1930720

Editor(s):

(1) Dr. Francisco Cruz-Sosa, Metropolitan Autonomous University, Mexico.

Reviewers:

(1) Nazia Akbar, Hazara University, Pakistan.

(2) Cristina-Crenguta Albu, Carol Davila University of Medicine and Pharmacy, Romania.

Complete Peer review History: <http://www.sdiarticle4.com/review-history/59829>

Original Research Article

Received 01 June 2020

Accepted 06 August 2020

Published 26 August 2020

ABSTRACT

The aim of this present clinical trial study is evaluate the efficacy of triclosan coated sutures versus chlorhexidine coated sutures in preventing surgical site infection after removal of an impacted mandibular third molar. This prospective, single blind study included 30 patients divided into two groups with 15 patients each who had been referred to the Oral Surgery Clinic at Department of Oral and Maxillofacial Surgery, Saveetha Dental College, Chennai for surgical removal of impacted mandibular third molar under local anaesthesia. The patients were randomly assigned to two groups: Group 1 were treated with (3-0) antimicrobial triclosan impregnated polyglactin sutures for closure and in group 2 with (3-0) antimicrobial chlorhexidine diacetate-impregnated polyglactin sutures. Evaluation in regard to infection rate, abnormal erythema, pain and trismus between two groups was done on the 7th day postoperatively. In this study we observed that no significant difference in rates of infection between the groups. Abnormal erythema and trismus showed better

*Corresponding author: E-mail: senthilnathan@saveetha.com;

results in group 2(chlorhexidine group) on 7th day postoperatively whereas incidence of pain was higher in patients treated with chlorhexidine coated sutures on the 7th day postoperatively as compared to patients treated with triclosan coated sutures. However, P value was >0.05 which was considered statistically insignificant. Within the limitations of the present study, chlorhexidine diacetate-impregnated polyglactin sutures showed reduced infection rates,erythema and trismus as compared to triclosan impregnated polyglactin sutures in healthy patients undergoing surgical removal of third molar under local anesthesia.

Keywords: *Triclosan impregnated polyglactin sutures; chlorhexidine diacetate-impregnated polyglactin sutures; infection; erythema; swelling; pain; trismus; impacted mandibular third molar.*

1. INTRODUCTION

Surgical site infection (SSI) remains as one of the most frequent complications after surgery [1–4] in the maxillofacial region.

Suture materials used during surgery carry risk of postoperative wound infections and associated complications like bone infection, organ abscess, bacteraemia, endocarditis, sepsis [5–7]. Evidence suggests that the suture knot may act as a nidus or scaffold for bacterial colonization and replication that can ultimately result in SSI [8]. It has also been hypothesized that a certain “wicking” phenomenon, occurring more frequently with braided or multifilament suture materials, could be responsible for the diffusion of the infection in the wound [9].

Various studies indicate that the incidence of postoperative infections following the surgical removal of third molar ranges from 1 to 5.8% and the routine use of antibiotics is not a necessity for the prevention of such a low incidence of infection [10]. Antibiotic resistance is currently a serious concern, and it is estimated that 6–7% of patients who are given antibiotics have some kind of adverse reaction to it [10]. But as most patients may lack confidence in their surgeon who do not prescribe antibiotics, clinicians at times are forced to prescribe antibiotics following the procedure [11].

Recent research has been focusing on avoiding bacterial colonization of sutures by using various antibacterial coating. An antibacterial coating may prevent the adherence of bacteria on medical materials but it is not possible to kill bacteria that adhere to suture materials, once a bio-film has formed [12]. The presence of antibacterial coatings on sutures is thought to prevent delay in wound healing by limiting the ability of these opportunistic microbes to adhere on the sutures [13].

Among antimicrobials, triclosan and chlorhexidine have a broad antibacterial

spectrum as well as high biocompatibility indices. The search for a more appropriate suture material has resulted in various commercially available newer materials, like Triclosan, an antibacterial coated polyglactin 910 (vicryl plus*, Johnson and Johnson limited, India) and Chlorhexidine, an antibacterial coated polyglactin 910 (3-0) (PECTRYL®CS, Dolphin suture) which replace the conventional method of administering antibiotic in routine third molar surgeries and help in maximising antimicrobial benefits locally and reducing antibiotic load systemically and the complications that follow [14].

With a rich case bank established over 3 decades we have been able to publish extensively in our domain [15–25]. Based on this inspiration we aim to evaluate the efficacy of triclosan coated sutures versus chlorhexidine coated sutures in preventing surgical site infection after removal of an impacted mandibular third molar.

2. MATERIALS AND METHODS

2.1 Study Setup

This randomized prospective controlled clinical study was conducted among patients reporting to the outpatient dental department of oral surgery clinic at Saveetha Dental College, Chennai during the period between June 2019- March 2020. The study population included 30 adult patients who were randomly selected and had been referred to the department of oral and maxillofacial surgery for surgical removal of impacted mandibular third molar under local anaesthesia. The sample size was divided into two groups, each consisting of 15 patients, namely:

- (1) Group 1: Individuals who were given antimicrobial triclosan-impregnated 3–0 polyglactin sutures in a simple interrupted fashion without any antibiotics for closure of the surgical site.

- (2) Group 2: Individuals who were given antimicrobial chlorhexidine diacetate-impregnated 3–0 polyglactin sutures in a simple interrupted fashion without any antibiotics for closure of the surgical site.

2.2 Inclusion Criteria

- Patients above 18 years of age
- Patients with impacted mandibular third molar with no prior signs of clinical infection or pain with adequate mouth opening
- Patients with normal TMJ function
- Partial or complete bony impactions of mandibular third molars.

2.3 Exclusion Criteria

- Patients who have taken antibiotics prior, in a span of 2–3 weeks for any head and neck infections or upper respiratory tract (penicillin/cephalosporin).
- Patients with known allergic reactions to triclosan, chlorhexidine, beta-lactams and cephalosporins.
- Patients on drugs that might alter the course of study and affect the healing of the surgical site, e.g. aspirin, NSAIDs, steroids and cytotoxic drugs.
- Evidence of malnutrition or debilitation;
- Coexisting conditions that may impair wound healing including acquired immunodeficiency syndrome (AIDS)
- Patients lost to follow-up.
- Pregnancy and lactating mothers or oral contraceptives.
- Patients with poor oral hygiene and chronic smokers, chronic alcoholism

2.4 Procedure

All patients chosen for the study were prepared in standard aseptic conditions and the cases were operated utilising incisions and procedural steps through buccal bone guttering technique and tooth splitting as per the angulation, depth and position of the impacted mandibular third molar [26]. Following the third molar removal adequate curettage, debridement, thorough irrigation and the flaps were closed with triclosan-impregnated (3-0) polyglactin or chlorhexidine diacetate-impregnated (3–0) polyglactin. They were given saline mouthwashes postoperatively for 7 days to be

used thrice daily after the procedure. Patients were prescribed analgesics for 3 days postoperatively following which they were evaluated on 7th day after the day of surgery.

2.5 Diagnostic Criteria

Primary efficiency measure was the development of infection throughout the study period. The secondary outcome measures were abnormal erythema, trismus and pain.

2.5.1 Infection

Presence of purulent discharge in the extraction socket with or without swelling or pain.

Abnormal Erythema: Superficial reddening in mucosa seen as a result of injury or irritation causing dilatation of the blood capillaries. This was graded as:

- 0 = absence of any signs of erythema.
- 1 = presence of redness and hyperaemia around the surgical site.
- 2 = bleeding from the surgical site
- 3 = ulceration of the surgical site.

2.5.2 Trismus

Measurement was taken before and after surgery using a ruler and assessed on 7th day postoperatively. This was graded as:

- 0 = absence of any difference.
- 1 = decrease, less than 10 mm compared to pre-surgery.
- 2 = decrease, more than 10 mm pre-surgery.

2.5.3 Pain

This was evaluated on the 7th day post-operatively using a Visual Analogue Scale(VAS). Patients were asked to indicate their intensity of pain on a 5-level scale. The scale displayed five faces showing expressions which range from a minimum score of 1(No pain), 2 (Mild pain), 3(Moderate pain), 4(Severe pain)to score 5(Very Severe excruciating pain).This was graded as:

- 0 = absence of pain.
- 1 = pain assessment less than 5.

2.6 Study Parameters

The following data were extracted for the purpose of the study:

- Age of the patient
- Gender of the patient
- Incidence of wound infection
- Abnormal erythema
- Pain based on VAS Scale
- Trismus

The subjects were divided into four age groups- Group 1: 11-20 years, Group 2: 21-30 years, Group 3: 31-40 years, Group 4: 41-50 years.

2.7 Data Collection

The data related to the study parameters were obtained from among patients who reported to the Outpatient Department in Saveetha Dental College, Chennai from June 2019- March 2020. All assessments were done by a single examiner and the findings were reviewed and recorded by two investigators.

2.8 Statistical Analysis

The data was tabulated and analysed using IBM SPSS version 23.0 software. Non- parametric data were analysed using descriptive statistics measuring frequency and percentage. Student's t-test was used to compare variables (abnormal erythema, trismus and VAS Score 7th day post surgically) between both the groups. The significance level was set at $P < 0.05$ with a confidence interval of 95%. Pearson's Chi Square Test was used to assess the association between incidence of wound infection between both the groups (Triclosan and Chlorhexidine).

3. RESULTS AND DISCUSSION

A total of 30 patients participated in this study, with an overall 100% participation.

3.1 Age Distribution

The youngest and oldest patients were aged 18 and 50 years, respectively. The distribution of study subjects based on age revealed that most patients belonged to 21-30 years of age (46.67%) with the mean age of 25.42.

3.2 Gender Distribution

The distribution of study subjects based on gender, over a ten month period, revealed that 12 patients (40%) women and 18 patients (60%) men participated in this study.

3.3 Incidence of Infection

The incidence of infection in group 1 (triclosan) was numerically 3 out of 15 cases and in group 2 (Chlorhexidine) was 2 in 15 cases as evaluated on the 7th postoperative day. Necessary intervention was done and appropriate medications were prescribed as required. Pearson's Chi Square Test was used to assess the association between incidence of wound infection between both the groups (Triclosan and Chlorhexidine) on the 7th day postoperatively. However, this association was not statistically significant ($P > 0.05$).

3.4 Abnormal Erythema

There was a clear difference in the values of abnormal erythema between the groups in the 7th day postoperatively with a frequency distribution of abnormal erythema (grade 1) of 20% and 6.66% in group 1 and group 2, respectively. Therefore, patients treated with triclosan coated sutures showed a higher incidence of abnormal erythema as compared to patients treated with chlorhexidine coated sutures. However, P value was 0.16 which was considered statistically insignificant.

3.5 Trismus

There was a difference between the values in case of trismus assessed 7th day postoperatively with a frequency of 73.33% of no trismus in the chlorhexidine-impregnated suture group (group 2) as compared to 66.66% in triclosan-impregnated suture group (group 1), and <10 mm difference in maximum mouth opening from preoperative values as 33.33% in group 1 and 26.66% in group 2. Therefore, patients treated with triclosan coated sutures showed a higher incidence of trismus as compared to patients treated with chlorhexidine coated sutures. However, P value was > 0.05 which was considered statistically insignificant.

3.6 Pain Evaluated by VAS Score

On the 7th day postoperatively, there was amelioration of pain in either group and only one candidate (6.66%) in group 1 and two candidates (13.33%) in group 2 showed VAS score > 5 . Therefore, patients treated with chlorhexidine coated sutures showed a higher incidence of pain as compared to patients treated with triclosan coated sutures. However, P value was > 0.05 which was considered statistically insignificant.

Table 1. Distribution of variables

	Triclosan Group (Mean)	Chlorhexidine Group (Mean)	Test Value	P value
Abnormal Erythema	0.20	0.07	1.46	0.16
Trismus	0.33	0.27	0.36	0.71
Pain	0.07	0.13	-1.00	0.33

Table 1 the table depicts the distribution of variables (abnormal erythema, trismus and VAS Score 7th day post surgically) and comparative test results based on Students t-test between both the groups. Patients treated with triclosan coated sutures showed a higher incidence of abnormal erythema and trismus on the 7th day postoperatively as compared to patients treated with chlorhexidine coated sutures. However, P value was 0.16 and 0.71, respectively which was considered statistically insignificant. On the other hand, patients treated with chlorhexidine coated sutures showed a higher incidence of pain on the 7th day postoperatively as compared to patients treated with triclosan coated sutures. However, P value was 0.33 which was considered statistically insignificant.

Smart sutures are materials which are covered with temperature sensors and micro-heaters and can detect infections. If they are coated with antibacterial drugs, they might be highly effective in prevention of SSIs [27]. In spite of many controversial results amongst different clinical studies, the antimicrobial suture have proven to be more or less effective in decreasing the risk for postoperative SSIs in the maxillofacial region.

Physical properties and configuration of suture materials influence the degree of surgical site infection [28]. Triclosan is effective in significantly reducing the bacterial adherence to suture material which can decrease the SSI and morbidity [13]. The safety of triclosan is well established proving that it doesn't possess carcinogenic or sensitization potential [29]. Triclosan is an antiseptic component with bacteriostatic action. At low concentrations, inhibits the growth of many non sporulating gram positive and gram negative bacterial species [30]. The active component in coated polyglactin 910 suture with triclosan is Irgacare MP (triclosan), a broad-spectrum antiseptic agent that has been shown to be efficacious against these putative pathogens without inducing resistance [31–33].

Chlorhexidine is a widely used antimicrobial in various forms. It has shown high anti-infective

efficacy in several studies involving orthopaedic [34], obstetric [35], surgical [36] and dental applications [37]. Chlorhexidine diacetate is a bisbiguanide compound with a rapid bactericidal activity against both gram-positive and gram-negative organisms. The antibacterial effect of chlorhexidine is related to its action on the bacterial cell membrane and precipitation of intracellular contents configuring it with both bactericidal and bacteriostatic properties [38].

In our study, the incidence of infection in group 1 (triclosan) was numerically 3 out of 15 cases and in group 2 (Chlorhexidine) was 2 in 15 cases as evaluated on the 7th postoperative day. This was in accordance with the study by Mohan et al. [14] and Gazivoda et al. [39] and Venema et al. [40]. According to a review study by Zeitler et al., [10] the use of antibiotics tend to show little improvement in trismus. According to the study by Mohan et al. [14] follow up visits showed no statistical difference in patients treated with prophylactic antibiotics compared to those treated with chlorhexidine sutures in relation to trismus. This was in accordance with our study.

There seemed to also be a slight difference in values of abnormal erythema between the groups. According to a study Obermeier et al [41], the chlorhexidine laurate coating (CL11) molecularly similar to chlorhexidine diacetate which is chlorhexidine palmitate, best meets the medical requirements for a fast bacterial eradication. It also has a high drug release during the first clinically most relevant 48 h with a good biocompatibility. The lower incidence of erythema (6.66%) in the chlorhexidine group on the 7th day postoperatively, could be attributed to this reason which resulted in prevention of biofilm formation over the suture material. However, the difference was not statistically significant which was in accordance to the study by [14] and Ford et al. [8].

The postsurgical pain begins when the effect of the local anaesthesia subsides and reaches peak levels in 6–12 h postoperatively [42]. In our study, the patients were prescribed analgesics

pain control for the next 3 days postoperatively. On the 7th day postoperatively, there seemed to be a slightly higher incidence of pain in the chlorhexidine group (13.33%) as compared to the triclosan group which was in accordance with the study by Tae et al., [43]. However, according

to the study by Mohan et al., [14] which compared the efficacy of post surgical oral prophylactic antibiotics and chlorhexidine coated sutures, patients treated with the latter showed a decreased incidence of pain(5.79%) on the 7th day postoperatively.

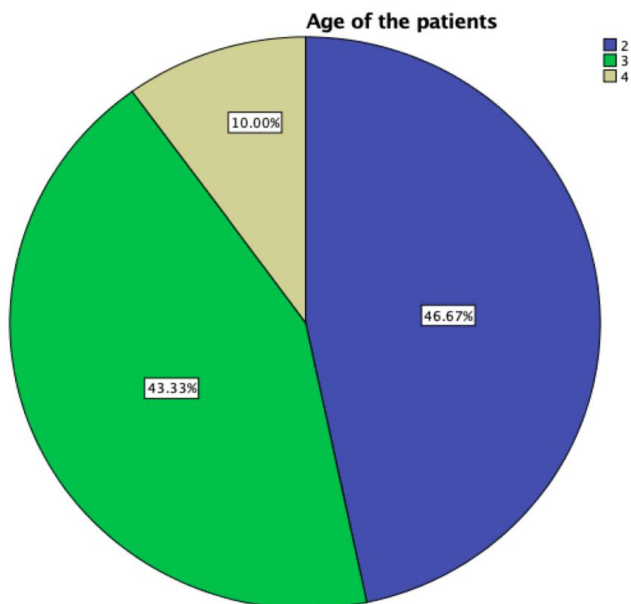


Fig. 1. The pie chart represents age as a baseline characteristic. The distribution of study subjects based on age revealed that most patients belonged to 21-30 years of age(46.67%) (blue)

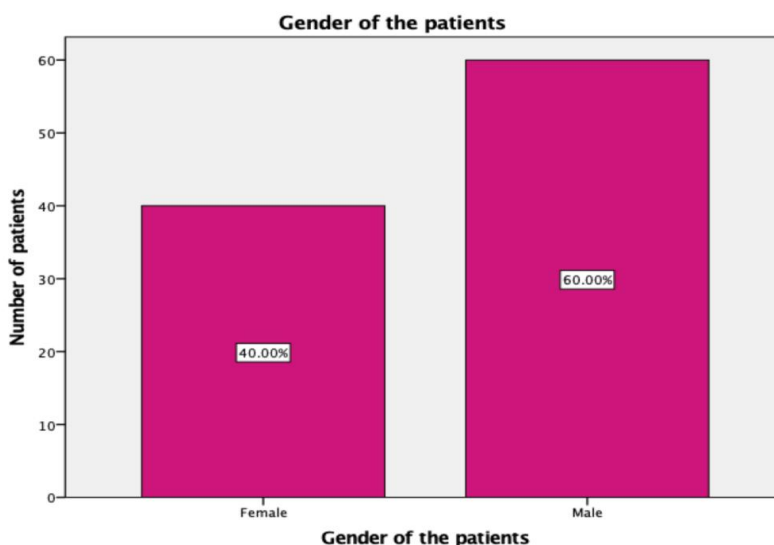


Fig. 2. This bar graph represents the gender related baseline characteristics of the patients. X Axis represents the gender and Y Axis represents the frequency of patients. The distribution of study subjects based on gender, over a ten month period, revealed that 12 patients (40%) were female and 18 patients(60%) were male

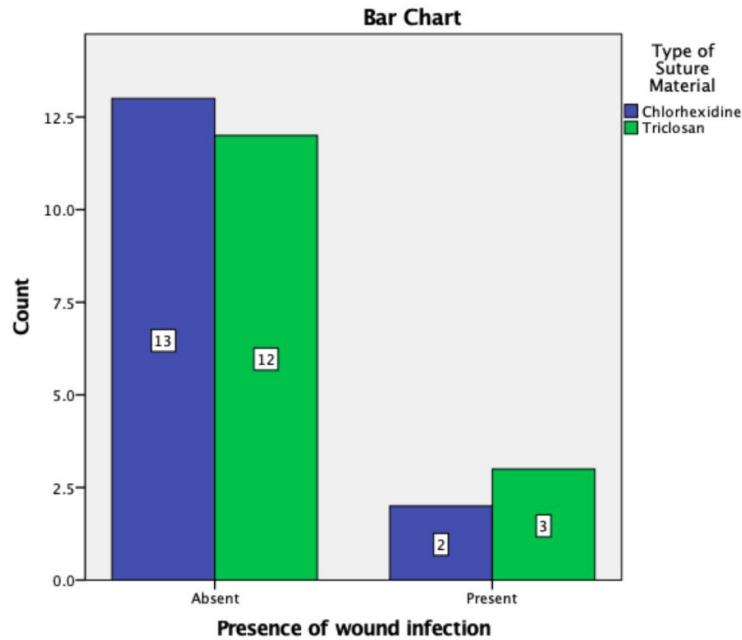


Fig. 3. The above bar graph represents the association between incidence of wound infection between both the groups (Triclosan and Chlorhexidine) on the 7th day postoperatively. X-Axis represents the presence of wound infection and Y-Axis represents the Number of patients. Pearson's Chi Square Test was used to assess the association between incidence of wound infection between both the groups (Triclosan and Chlorhexidine) on the 7th day postoperatively. However, this association was not statistically significant, $P=0.5$ ($P>0.05$)

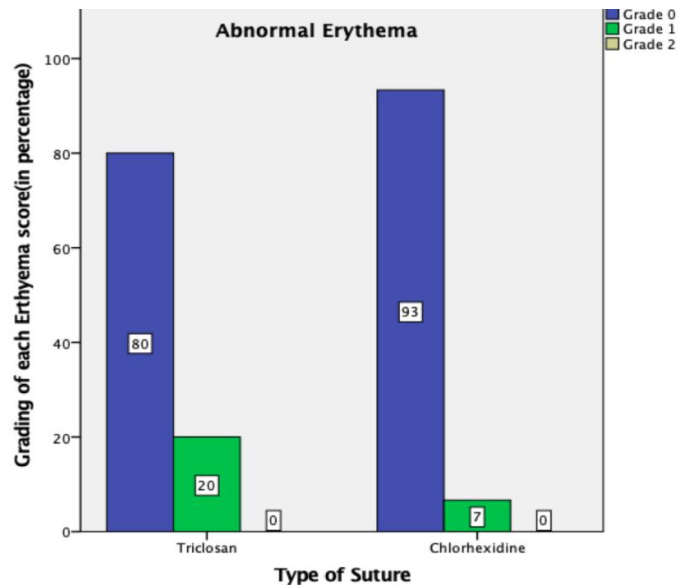


Fig. 4. The above bar graph depicts the abnormal erythema associated with the triclosan group and chlorhexidine group at the 7th post operative day. The X-Axis represents the type of suture and the Y-Axis represents the Percentage of the Scores of each grading in relation to erythema. The patients treated with triclosan coated sutures showed a higher incidence of abnormal erythema (grade 1): (20%) as compared to patients treated with chlorhexidine coated sutures. (6.66%)

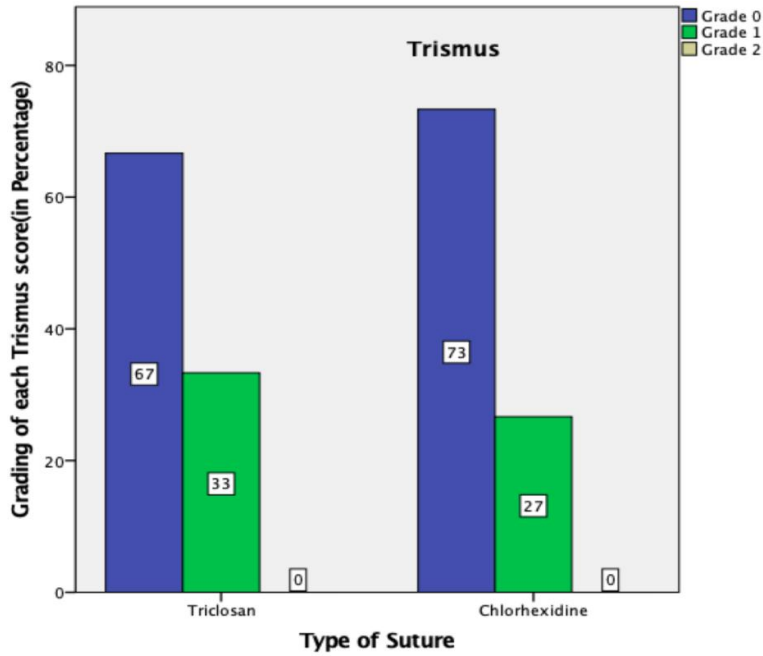


Fig. 5. The above bar graph depicts the trismus associated with the triclosan group and chlorhexidine group at the 7th post operative day. The X-Axis represents the type of suture and the Y-Axis represents the Percentage of the Scores of each grading in relation to Trismus. The patients treated with triclosan coated sutures showed a higher incidence of trismus(33.33%) as compared to patients treated with chlorhexidine coated sutures.(26.66%)

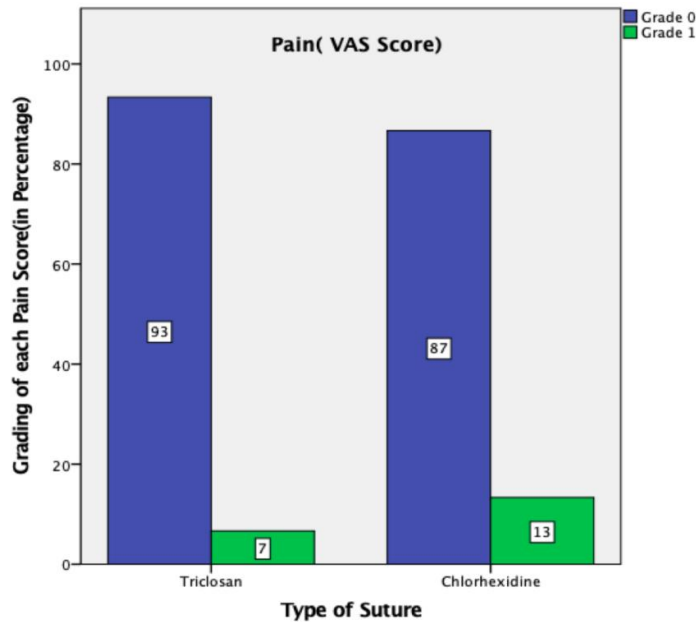


Fig. 6. The above bar graph depicts the pain associated with the triclosan group and chlorhexidine group at the 7th postoperative day. The X-Axis represents the type of suture and the Y-Axis represents the Percentage of the Scores of each grading in relation to Pain. The patients treated with chlorhexidine coated sutures showed a higher incidence of pain(13.33%) as compared to patients treated with triclosan coated sutures.(6.66%)

4. FUTURE SCOPE

Triclosan impregnated polyglactin sutures and chlorhexidine diacetate-impregnated polyglactin sutures have both been introduced recently in the field of dentistry with no adverse effects being documented. However, the use of chlorhexidine sutures show properties closer to an ideal suture material in comparison to triclosan sutures.

5. LIMITATIONS

Future clinical studies with larger sample sizes are needed to accurately compare and evaluate the efficacy of triclosan impregnated sutures with chlorhexidine impregnated sutures in minor oral surgical procedures.

6. CONCLUSION

Within the limits of this study, it can be concluded that both triclosan and chlorhexidine impregnated polyglactin sutures have a significant ability in preventing surgical site infection. However, chlorhexidine sutures showed reduced infection rates, erythema and trismus as compared to triclosan sutures in healthy patients undergoing surgical removal of third molar under local anesthesia. Therefore, their use in various intraoral procedures for effective control of inflammatory and infectious conditions should be highlighted.

CONSENT AND ETHICAL APPROVAL

Approval for the study was obtained from the Institutional Ethical Committee of Saveetha University (SDC/SIHEC/2020/DIASDATA/0619-0320). Informed consent was obtained from the patients.

ACKNOWLEDGEMENTS

The authors would like to acknowledge the help and support rendered by the Department of Oral and Maxillofacial Surgery and Information Technology of Saveetha Dental College and Hospitals for their constant assistance with the research.

COMPETING INTERESTS

Authors have declared that no competing interests exist.

REFERENCES

1. Chiu CC, Cheng TC, Chuang YC. Surgical-site infection (Br J Surg 2010;97:1601-1602). Br J Surg. 2011;98:460-460.
2. Leaper DJ, Van Goor H, Reilly J. Surgical site infection—a European perspective of incidence and economic burden. Int Wound J; 2004. Available: <https://onlinelibrary.wiley.com/doi/abs/10.1111/j.1742-4801.2004.00067.x>
3. Carvalho RLR de, Campos CC, Franco LM de C, et al. Incidence and risk factors for surgical site infection in general surgeries. Rev Lat Am Enfermagem. 2017;25:2848.
4. Mody P, Ali I, Shetty V, et al. A comparative study to test the effectiveness of triclosan coated polyglactin 910 in reduction of surgical site infection in clean wounds. International Surgery Journal. 2019;6:1182.
5. Giglio JA, Rowland RW, Dalton HP, et al. Suture removal-induced bacteremia: a possible endocarditis risk. J Am Dent Assoc. 1992;123:65-6:69-70.
6. King RC, Crawford JJ, Small EW. Bacteremia following intraoral suture removal. Oral Surg Oral Med Oral Pathol. 1988;65:23-28.
7. Otten JE, Wiedmann-Al-Ahmad M, Jahnke H, et al., Bacterial colonization on different suture materials—A potential risk for intraoral dentoalveolar surgery. J Biomed Mater Res. 2005;74B:627-635.
8. Ford HR, Jones P, Gaines B, et al., Intraoperative handling and wound healing: controlled clinical trial comparing coated VICRYL® Plus antibacterial suture (coated polyglactin 910 suture with triclosan) with Coated VICRYL® suture (coated polyglactin 910 suture). Surg Infect. 2005;6:313-321.
9. Lilly GE. Reaction of oral tissues to suture materials. Oral Surg Oral Med Oral Pathol. 1968;26:128-133.
10. Zeitler DL. Prophylactic antibiotics for third molar surgery: a dissenting opinion. J Oral Maxillofac Surg. 1995;53:61-64.
11. Bezerra TP, Studart-Soares EC, Scaparo HC, et al. Prophylaxis versus placebo treatment for infective and inflammatory complications of surgical third molar removal: A split-mouth, double-blind, controlled, clinical trial with amoxicillin (500 mg). Journal of Oral and Maxillofacial Surgery. 2011;69:333-339.
12. Donlan RM, Costerton JW. Biofilms: survival mechanisms of clinically relevant

- microorganisms. Clin Microbiol Rev. 2002;15:167–193.
13. Kruthi N, Rajasekhar G, Anuradha B, et al., Polyglactin 910 vs. triclosan coated polyglactin 910 in oral surgery: A comparative in vivo study. Dentistry. 2014;4:1.
 14. Mohan S, Jayanth BS, Saralaya S, et al. Comparative Study on the Efficacy of Postsurgical Oral Prophylactic Antibiotic Versus Antimicrobial Suture Placement Alone in Preventing Surgical Site Infection After Removal of Impacted Mandibular Third Molar. Journal of Maxillofacial and Oral Surgery. Epub ahead of print; 2019. DOI: 10.1007/s12663-019-01267-0
 15. Senthil Kumar MS, Ramani P, Rajendran V, et al. Inflammatory pseudotumour of the maxillary sinus: clinicopathological report. Oral Surg. 2019;12:255–259.
 16. Wahab PUA, Madhulaxmi M, Senthilnathan P, et al., Scalpel Versus Diathermy in Wound Healing After Mucosal Incisions: A Split-Mouth Study. J Oral Maxillofac Surg. 2018;76:1160–1164.
 17. J PC, Marimuthu T, C K, et al. Prevalence and measurement of anterior loop of the mandibular canal using CBCT: A cross sectional study. Clin Implant Dent Relat Res. 2018;20:531–534.
 18. Eapen BV, Baig MF, Avinash S. An Assessment of the Incidence of Prolonged Postoperative Bleeding After Dental Extraction Among Patients on Uninterrupted Low Dose Aspirin Therapy and to Evaluate the Need to Stop Such Medication Prior to Dental Extractions. J Maxillofac Oral Surg. 2017;16:48–52.
 19. Marimuthu M, Andiappan M, Wahab A, et al. Canonical Wnt pathway gene expression and their clinical correlation in oral squamous cell carcinoma. Indian J Dent Res. 2018;29:291–297.
 20. Jain M, Nazar N. Comparative Evaluation of the Efficacy of Intraligamentary and Supraperiosteal Injections in the Extraction of Maxillary Teeth: A Randomized Controlled Clinical Trial. J Contemp Dent Pract. 2018;19:1117–1121.
 21. Abhinav RP, Selvarasu K, Maheswari GU, et al. The Patterns and Etiology of Maxillofacial Trauma in South India. Ann Maxillofac Surg. 2019;9:114–117.
 22. Sweta VR, Abhinav RP, Ramesh A. Role of Virtual Reality in Pain Perception of Patients Following the Administration of Local Anesthesia. Ann Maxillofac Surg. 2019;9:110–113.
 23. Abdul Wahab PU, Senthil Nathan P, Madhulaxmi M, et al. Risk Factors for Post-operative Infection Following Single Piece Osteotomy. J Maxillofac Oral Surg. 2017;16:328–332.
 24. Ramadorai A, Ravi P, Narayanan V. Rhinocerebral Mucormycosis: A prospective analysis of an effective treatment protocol. Ann Maxillofac Surg. 2019;9:192–196.
 25. Patil SB, Durairaj D, Suresh Kumar G, et al. Comparison of extended nasolabial flap versus buccal fat pad graft in the surgical management of oral submucous fibrosis: A prospective pilot study. J Maxillofac Oral Surg. 2017;16:312–321.
 26. Mohan S, Jayanth BS, Saralaya S, et al. Comparative Study on the Efficacy of Postsurgical Oral Prophylactic Antibiotic Versus Antimicrobial Suture Placement Alone in Preventing Surgical Site Infection After Removal of Impacted Mandibular Third Molar. J Maxillofac Oral Surg. 2019:1–6.
 27. Sivakumar P, Naseem I. Biosmart materials the future of dentistry: A review. Research Journal of Pharmacy and Technology. 2016;9:1737–1742.
 28. Edlich RF, Panek PH, Rodeheaver GT, et al., Physical and chemical configuration of sutures in the development of surgical infection. Ann Surg. 1973;177: 679–688.
 29. Barbolt TA. Chemistry and safety of triclosan, and its use as an antimicrobial coating on Coated VICRYL* Plus Antibacterial Suture (coated polyglactin 910 suture with triclosan). Surg Infect. 2002;3(1):45–53.
 30. Sala-Pérez S, López-Ramírez M, Quinteros-Borgarello M, et al. Antibacterial suture vs silk for the surgical removal of impacted lower third molars. A randomized clinical study. Med Oral Patol Oral Cir Bucal. 2016;21:95–102.
 31. Bamber AI, Neal TJ. An assessment of triclosan susceptibility in methicillin-resistant and methicillin-sensitive *Staphylococcus aureus*. J Hosp Infect 1999; 41: 107–109.
 32. Zafar AB, Butler RC, Reese DJ, et al. Use of 0.3% triclosan (Bacti-Stat) to eradicate an outbreak of methicillin-resistant *Staphylococcus aureus* in a neonatal nursery. Am J Infect Control. 1995;23:200–208.
 33. Webster J, Faoagali JL, Cartwright D. Elimination of methicillin-resistant

- Staphylococcus aureus* from a neonatal intensive care unit after hand washing with triclosan. *J Paediatr Child Health*. 1994;30:59–64.
34. Darouiche RO, Farmer J, Chaput C, et al. Anti-Infective Efficacy of Antiseptic-Coated Intramedullary Nails*†. *The Journal of Bone & Joint Surgery*. 1998;80:1336–1340.
35. Vorherr H, Ulrich JA, Messer RH, et al. Antimicrobial effect of chlorhexidine on bacteria of groin, perineum and vagina. *J Reprod Med*. 1980;24:153–157.
36. Fardai O, Turnbull RS. A review of the literature on use of chlorhexidine in dentistry. *J Am Dent Assoc*, Available: [https://jada.ada.org/article/S0002-8177\(86\)26020-1/abstract](https://jada.ada.org/article/S0002-8177(86)26020-1/abstract) (1986).
37. Suido H, Offenbacher S, Arnold RR. A clinical study of bacterial contamination of chlorhexidine-coated filaments of an interdental brush. *J Clin Dent*. 1998;9:105–109.
38. Sanchez IR, Nusbaum KE, Swaim SF. Chlorhexidine Diacetate and Povidone-iodine Cytotoxicity to Canine Embryonic Fibroblasts and *Staphylococcus aureus*. *Veterinary*; 1998. Available:<https://onlinelibrary.wiley.com/doi/abs/10.1111/j.1532-950X.1988.tb00995.x>
39. Gazivoda D, Pelemiš D, Vujašković G. A clinical study on the influence of suturing material on oral wound healing. *Vojnosanit Pregl*. 2015;72:765–769.
40. Venema S, Abbas F, van de Belt-Gritter B, et al. In vitro oral biofilm formation on triclosan-coated sutures in the absence and presence of additional antiplaque treatment. *J Oral Maxillofac Surg*. 2011;69:980–985.
41. Obermeier A, Schneider J, Harrasser N, et al. Correction: Viable adhered *Staphylococcus aureus* highly reduced on novel antimicrobial sutures using chlorhexidine and octenidine to avoid surgical site infection (SSI). *PLoS One*. 2018;13:0193284.
42. Deliverska EG, Petkova M. Complications after extraction of impacted third molars-literature review. *Journal of IMAB--Annual Proceeding Scientific Papers*. 2016;22:1202–1211.
43. Tae BS, Park JH, Kim JK, et al. Comparison of intraoperative handling and wound healing between (NEOSORB® plus) and coated polyglactin 910 suture (NEOSORB®): A prospective, single-blind, randomized controlled trial. *BMC Surg*. 2018;18:45.

© 2020 Krishnan et al.; This is an Open Access article distributed under the terms of the Creative Commons Attribution License (<http://creativecommons.org/licenses/by/4.0>), which permits unrestricted use, distribution, and reproduction in any medium, provided the original work is properly cited.

Peer-review history:
The peer review history for this paper can be accessed here:
<http://www.sdiarticle4.com/review-history/59829>