

## **A Case Study of Rabies in a Two Month Old Bull Calf in Bauchi, Nig**

**M. Dauda<sup>1\*</sup>, Y. J. Atuman<sup>2,3</sup>, G. S. N. Kia<sup>4</sup>, D. O. Omoniwa<sup>5</sup> and I. S. Tekki<sup>2</sup>**

<sup>1</sup>*Regional Disease Surveillance Enhancement Project (REDISSE), Ministry of Agriculture and Animal Husbandry, Gombe, Gombe State, Nigeria.*

<sup>2</sup>*Diagnostic and Extension Services Department, National Veterinary Research Institute, Vom, Nigeria.*

<sup>3</sup>*Clinic of the National Veterinary Research Institute, Bauchi Outstation Laboratory, Bauchi State, Nigeria.*

<sup>4</sup>*Department of Veterinary Public Health and Preventive Medicine, Ahmadu Bello University, Zaria, Nigeria.*

<sup>5</sup>*Department of Veterinary Medicine, Surgery and Radiology, University of Jos, Nigeria.*

### **Authors' contributions**

*This work was carried out in collaboration among all authors. Author MD designed the study, performed the statistical analysis, wrote the protocol and wrote the first draft of the manuscript. Authors YJA, GSNK and DOO managed the literature searches and editing of the manuscript. Author IST laboratory managed the analyses of the study. All authors read and approved the final manuscript.*

### **Article Information**

#### Editor(s):

(1) Dr. Fabio da Costa Henry, State University of Northern of Rio de Janeiro, Brasil.

#### Reviewers:

(1) Surbhi K. Tyagi, Sardar Vallabhbhai Patel University of Agriculture & Technology, India.

(2) Arun Kumar Sharma, Junagadh Agricultural University, India.

Complete Peer review History: <http://www.sdiarticle4.com/review-history/61631>

**Case Study**

**Received 20 July 2020**

**Accepted 25 September 2020**

**Published 16 October 2020**

### **ABSTRACT**

On 8<sup>th</sup> November, 2019, a herdsman brought a complain to the clinic of the National Veterinary Research Institute, Bauchi outstation laboratory, Bauchi state, Nigeria, of his 2-month-old calf which was bitten 6-weeks ago by his unvaccinated suspected rabid dog, which was responsible for guarding the cattle herd. The calf had been showing some nervous signs and was unable to suckle 2 days prior to the case presentation. During a visit to the herd, the following observations were made on the calf: abnormal bellowing, drooling salivation, emaciation, hypersensitivity, inability to suckle, straining, dehydration, epilation and scars of healed wounds on the forelimbs. The calf was

\*Corresponding author: E-mail: [mishelbatari123@gmail.com](mailto:mishelbatari123@gmail.com);

euthanized, a portion of the brain was collected and sent to Rabies Laboratory of the National Veterinary Research Institute, Vom, Plateau state, Nigeria for confirmatory diagnosis using direct fluorescent antibody test (FAT). The brain tissue sample was positive for rabies. The hard to reach nomadic cattle herders with rabies unvaccinated dogs guarding their herds could hinder rabies national control and elimination program. Although cattle are dead-end hosts, human exposure is possible due to close contact which may expose man to infected saliva, aerosol and splashes of infected tissues at slaughter. Therefore, there is need for equitable transfer of knowledge on prompt reporting of dog bite cases and urgent national implementation of strategic rabies elimination program to prevent economic losses or/and rabies transmission to humans.

*Keywords: Zoonoses; FAT; quarantine; euthanasia; rabies; bull- calf.*

## 1. INTRODUCTION

Rabies is a disease caused by a bullet shaped, negative stranded- ribonucleic acid (RNA) virus of approximately 12kilo base pairs (kbp), belonging to the genus *Lyssavirus* in the family *Rhabdoviridae* and order *Mononegavirales* [1, 2,3] Rabies virus infects the central nervous system (CNS) of man and other warm blooded animals resulting in death once clinical symptoms and signs set in [4]. The incubation period of the rabies virus varies between 21-80 days in dogs, but up to 209 days in horses and cattle, depending on the proximity of bite to the CNS [5,4]. Its implications are especially apparent in poverty-stricken less-developed countries, and are a significant public health threat for two-thirds of the world's population, being endemic across most of Africa and Asia [1,6]. Dog bites expose victims to many potential zoonoses, especially rabies which is feared because of the high case fatality rate of almost 100% [7].

The clinical disease in cattle first manifests as change in natural behaviour, excessive salivation, excitability, mania and ends in motor paralysis and death [4]. In man and cattle mortality is approximately 100% and susceptibility depends on region and the biotype of the virus [5]. Furthermore, young animals are more susceptible than adults, the disease can be prevented through vaccination of domestic dogs and cattle, while control is through quarantine, test and slaughter of confirmed cases [8]. In addition to mechanisms that reduce rabies in domestic dogs, the availability of simple and affordable diagnostics will enhance reporting and identify areas where the disease is most burdensome [9]. Poor record system and absence of diagnostic laboratory in most states has further worsened the situation in Nigeria [10]. Canine rabies was eliminated from many regions through Veterinary service initiatives. The

program includes the mandatory registration and vaccination of dogs and responsible dog ownership [11]. Laboratory-based surveillance has overtime proven to be the effective rabies prevention and control strategy. The prove of the absence of the disease also depend on rapid data reporting and an adequate system of risk assessment [12].

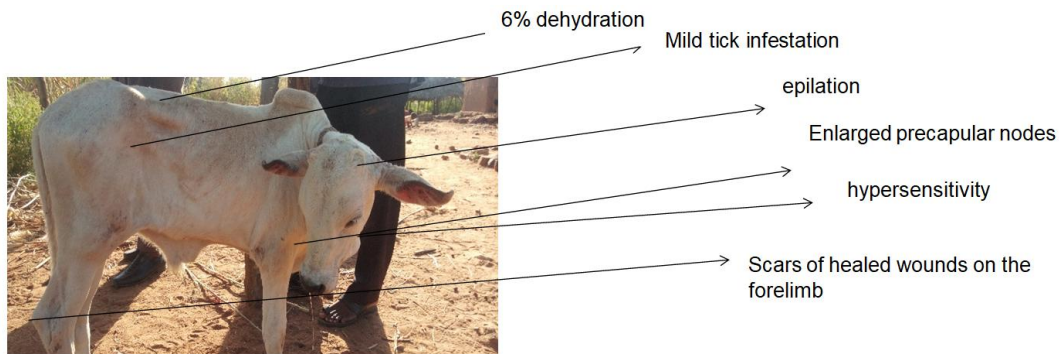
## 2. CASE REPORT

A Bull calf of two month age belonging to the herdsman from Burgel community in Dass brought to the clinic of the National Veterinary Research Institute, Bauchi outstation laboratory, Bauchi state, Nigeria on 8<sup>th</sup> November 2019.

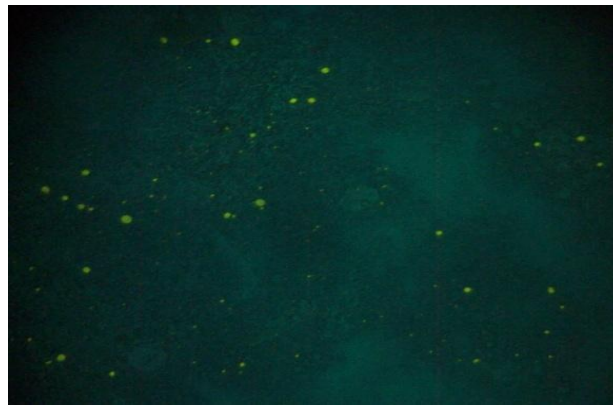
The calf unable to suckle, had drooling salivation, and was showing nervous manifestations. History revealed that a cow in the herd was slaughtered on the same day, and then sold to butchers after showing similar signs as the calf. During a visit to the herd, it was confirmed that an unvaccinated dog that usually guards the herd, was euthanized by the herdsman after showing some nervous manifestations six weeks ago. The symptoms noticed in calf two days prior to the day the complaint was made.

### 2.1 Clinical Findings

During a visit to the herd, the following signs were seen: Abnormal bellowing, drooling salivation (Plate 1), emaciation (Plate 1), Enlarged prescapular lymphnodes (bilateral), inability to suckle, 6% dehydration (loss of skin elasticity 4-8 secs), hypersensitivity, mild ticks' infestation, epilation and scars of healed wounds on the forelimb. Postmortem examination was conducted, the brain was extracted, packaged with ice pack as described elsewhere [13] and sent to the National Veterinary Research Institute, Vom, Plateau state, Nigeria for a confirmatory diagnosis.



**Plate 1. The emaciated calf with drooling salivation**



**Plate 2. Direct Fluorescent antibody test (FAT) photomicrograph showing brilliant apple green fluorescein particles indicating positive result for rabies viral antigen**

## 2.2 Laboratory Diagnosis

### 2.2.1 Direct fluorescent antibody test

A working dilution of 1:40 of the rabies direct fluorescent antibody assay was achieved following titration assay reagent (Monoclonal antibody-conjugate) by Fujirebio Inc. Diagnostic in accordance with manufacturer's recommendations and as described by [14]. Briefly, a small fraction of the brain sample was smeared using wire loop on one part of a slide pressed on a disposable tissue to allow for an even spread and to obtain an impression smear. This smear was allowed to air dry and was fixed in cold acetone for one hour at  $-20^{\circ}\text{C}$ . The slides were then air dried and rabies conjugate was applied to cover the smear further incubated for 30 minutes at  $37^{\circ}\text{C}$  in a humid chamber, after which excess conjugate was removed from the slides by rinsing it with 7.4 pH PBS solution about 3-5 minutes and then allowed to air dry. Then cover slips were mounted with buffered Glycerol Mounting medium and the slides were

examined using a Fluorescent microscope (Carl Zeiss, Germany) within 2 hours after staining. The test considered positive when there is an appearance of brilliant apple-green fluorescence coloured particles of varying size exhibited against a black background. If no specific apple-green fluorescence is exhibited the test is considered negative.

The laboratory result was positive for direct FAT and graded as +++ (Plate 2). It was confirmatory for rabies.

## 3. RESULTS AND DISCUSSION

This case serves as an important reminder of the risk of rabies via cattle to herders, Veterinarians, animal health workers and butchers in Bauchi State, Nigeria. As previously, reported [2], the cases of rabies in dogs at Bauchi, Gombe and Abeokuta were many with some cases reported in atypical hosts such as food animals (Cattle, sheep and goats) Prior to this case of the calf presented, one of the cattle in the herd was

bitten by the same offending dog, later showed nervous signs and anorexia and was sold to a butcher and slaughtered for public consumption, this is of immense public health concern as exposure could result in the process of cutting and meat preparation. The nomads might have done so out of ignorance on the dangers of rabies to human health which corroborates with the previous report of [15] on the lack of knowledge on the dangers of rabies among the general populace in Bauchi State. Efforts to initiate contact tracing of the butchers who handled the processing of the slaughtered cattle for advice on post exposure prophylaxis was vehemently rejected by the nomads, hence the need for awareness on the dangers of rabies.

Although dogs are the known primary reservoirs of rabies in Nigeria [3,7], reports of rabies in livestock such as cattle in Nigeria is on the increase [8], hence, this could predispose humans whose occupation makes them to be at risk of getting infected through saliva, tissues and other body fluids during handling, slaughter, processing of these animals and their by-products. The calf manifested hyper salivation, inability to suckle and abnormal bellowing similar to the signs reported in the cases of rabies in calves by [4,8] in Zaria, Kaduna State Nigeria. The owners said the offending suspected rabid dog that bit the two cattle had never been vaccinated against rabies similar to earlier reports by [4,16], that nomadic herdsmen in Nigeria keep dogs for security purposes, but routine vaccination against rabies is not taken into consideration and the dogs stand a high risk of exposure as they mix with stray dogs around.

Both [15,17] reported low rabies vaccination coverage among dogs in Bauchi State Nigeria, this might probably be the reasons for the current outbreak as the calf was bitten by an unvaccinated dog on the farm. The need for awareness campaign on responsible dog ownership among nomads in Bauchi State cannot be over emphasized. This will enable them develop the habit to routinely vaccinate their dogs and most importantly curtail the spread of rabies among dogs, livestock and humans. The presence of the disease in both livestock and wildlife in Nigeria in most cases is associated with unvaccinated dogs as the primary source [2,16,8]. There is need for concerted efforts in Nigeria towards rabies elimination by mounting consistent rabies awareness campaigns using all relevant avenues and social media platforms alongside annual

country-wide free mass anti-rabies vaccination of all dogs against the disease in the Country.

#### 4. CONCLUSION

Rabies in cattle may present economic challenge in the livestock industry with sequential public health impact. The use of cattle guard dogs by nomadic herdsmen to secure their cattle herds is an ancient tradition but compliance with vaccination against rabies should be mandatory requirement to enjoying this canine service. There is a need to educate nomadic herdsmen about rabies prevention and control and to teach them how to recognize the disease when it occurs in their animals to encourage prompt reporting.

#### CONSENT

The calf was then euthanized after seeking the consent of the owner.

#### COMPETING INTERESTS

Authors have declared that no competing interests exist.

#### REFERENCES

1. Dietzgen RG, Calisher CH, Kurath G, Kuzmin IV, Rodriguez LL, Stone DM, Whitfield AE. Family *rhabdoviridae*. In: King, M.J.A.A.M.Q., Carstens, E.B. & E.J.L. (Eds.), Virus Taxonomy Ninth Report of the International Committee on Taxonomy of Viruses. Elsevier Academic Press. 2011;686–714.
2. Tekki IS, Meseko CA, Omotainse SO, Atuman YJ, Chukwukere O, Olaleye S., Okewole PA. Incidences of rabies in domestic animals and consequent risk factors in humans. Journal of Medical Microbiology & Diagnosis, 2014;3:143. DOI: 10.4172/2161-0703.1000143
3. Kia GSN, Huang Y, Zhou M, Zhou Z, Gnanadurai CW, Leysona CM, Umoh JU, Kazeem HM, Ehizibolo DO, Kwaga JKP, Nwosu CI, Fu ZF. Molecular Characterization of a Rabies Virus Isolated from Trade Dogs in Plateau State, Nigeria. Sokoto Journal of Veterinary Sciences. 2018;16(2):54-62.
4. Mshelbwala PP, Audu SW, Ogunkoya AB, Okaiyeto SO, Abdullahi SU. A case study of rabies in a six-month-old calf in Zaria, Nigeria. Journal of Experimental Biology

- and Agricultural Science. 2013;1(4):218-22.
5. Bizimenyera ES. Rabies in a two weeks old calf Near, Kampala: A case report. Rabies diagnosis Challenge and opportunities; 1998.  
Available:<http://searg.info/fichiers/articles/1999086087L.PDF> accessed on April 09, 2013.
  6. Hampson K, Dobson A, Kaare M, Dushoff J, Magoto M, Sindoya E, Cleaveland S. Rabies exposures, post-exposure prophylaxis and deaths in a region of endemic canine rabies. PLoS Neglected Tropical Disease. 2008;2(11):e339.
  7. Konzing L, Kwaga JKP, Kia GSN, Kazeem HM. A Retrospective Study of Dog Bite Cases Reported to Some Hospitals in Plateau State, Nigeria Sokoto Journal of Veterinary Sciences 2019;17(1):56-61.
  8. Ibrahim S, Audu SW, Usman A, Kaltugo BY. Rabies in a Six-Week Old Bunaji-Bull Calf in Zaria: A Case Report. Journal of Microbes and Microbiology Techniques. 2017;1(1):101.
  9. Hossain M, Ahmed K, Bulbul T, Hossain S, Rahman A, Biswas MN, Nishizono A. Human rabies in rural Bangladesh. Epidemiol. Infect. 2012;140(11):1964–1971.
  10. Ogunkoya AB, Audu SW, Mshelbwala PP, Atuman YJ, Ehimiyein AM, Osinubi MOV, Garba A, Abidoye EO, Onoja IE. Problems of Rabies in Nigeria: A review. 1<sup>st</sup> International conference on Rabies in west Africa (RIWA), held at International conference center University of Ibadan , Nigeria. December 4 - December 7, 2012.
  11. Blanton JD, Dyer J, McBrayer J, Rupprecht CE. Rabies surveillance in the United States during 2011. J. Am. Vet. Med. Assoc. 2015;241(6):712–722.
  12. Ashley C, Banyard AC, Horton DL, Freuling C, Müller T, Fooks AR. Control and prevention of canine rabies: The need for building laboratory-based surveillance capacity. Antiviral Research. 2013;98(3):357-364.
  13. Kaplan MM, Koprowski H. Rabies. Scientific American. 1980;2;103-114.
  14. Hampson K, Coudeville L, Lembo T, Sambo M, Kieffer A. Estimating the global burden of endemic canine rabies. PLoS Neglected Tropical Diseases. 2015;9(4):e0003709.
  15. Atuman YJ, Ogunkoya AB, Adawa DAY, Nok AJ, Biallah MB. Dog ecology, dog bites and rabies vaccination rates in Bauchi State, Nigeria. International Journal of Veterinary Science and Medicine. 2014a;2:41–45.
  16. Atuman YJ, Adawa DAY, Audu SW, Mshelbwala PP, Ogunkoya AB. Potential risks for rabies spill-over from apparently healthy dogs to wildlife in Bauchi state, Nigeria. Journal of Veterinary Advances. 2014b;4(4):493-498.  
DOI:10.5455/jva.20140418115203
  17. Bolajoko MB, Atuman YJ. Rabies Ecology in Bauchi State, Nigeria Journal of Veterinary and Biomedical Sciences. 2019;2(1):5-12.

© 2020 Dauda et al.; This is an Open Access article distributed under the terms of the Creative Commons Attribution License (<http://creativecommons.org/licenses/by/4.0>), which permits unrestricted use, distribution, and reproduction in any medium, provided the original work is properly cited.

*Peer-review history:*  
*The peer review history for this paper can be accessed here:*  
<http://www.sdiarticle4.com/review-history/61631>

+