



# **Diverticular Peritonitis Revealing an Incidental Neuroendocrine Tumor of the Appendix: A Rare Case Report and Review of the Literature**

**Bouali Mounir <sup>a</sup>, El Kinani Siham <sup>a</sup>, El Azhari Ilias <sup>a\*</sup>,  
Majd Abdessamad <sup>a</sup>, Kamal Khadija <sup>a</sup>,  
El Bakouri Abdelilah <sup>a</sup>, El Hattabi Khalid <sup>a</sup>,  
Bensardi Fatima Zahra <sup>a</sup>, Fadil Abdelaziz <sup>a</sup>,  
Khadija Rebbouh <sup>b</sup>, Houria Tabakh <sup>b</sup>, Abdellatif Siwane <sup>b</sup>,  
Najwa Touil <sup>b</sup>, Omar Kacimi <sup>b</sup> and Nabil Chikhaoui <sup>b</sup>**

<sup>a</sup> Department of Visceral Surgery Emergency p35, University Hospital Center Ibn Rochd, Casablanca, Morocco.

<sup>b</sup> Department of Emergency Radiology, University Hospital Center Ibn Rochd, Casablanca, Morocco.

## **Authors' contributions**

*This work was carried out in collaboration among all authors. All authors read and approved the final manuscript.*

## **Article Information**

### **Open Peer Review History:**

This journal follows the Advanced Open Peer Review policy. Identity of the Reviewers, Editor(s) and additional Reviewers, peer review comments, different versions of the manuscript, comments of the editors, etc are available here: <https://www.sdiarticle5.com/review-history/117817>

**Case Report**

**Received: 01/04/2024**

**Accepted: 04/06/2024**

**Published: 12/06/2024**

## **ABSTRACT**

Three main histological types of appendicular tumor have been described: adenoma, carcinoma and endocrine tumor. Endocrine tumors are the most common, accounting for almost two-thirds of appendicular tumors. Adenomas and adenocarcinomas are rare and present two particularities: A predominant and frequent mucinous component, and a privileged peritoneal extension.

\*Corresponding author: E-mail: [iliaselazhari@gmail.com](mailto:iliaselazhari@gmail.com);

**Cite as:** Mounir, Bouali, El Kinani Siham, El Azhari Ilias, Majd Abdessamad, Kamal Khadija, El Bakouri Abdelilah, El Hattabi Khalid, Bensardi Fatima Zahra, Fadil Abdelaziz, Khadija Rebbouh, Houria Tabakh, Abdellatif Siwane, Najwa Touil, Omar Kacimi, and Nabil Chikhaoui. 2024. "Diverticular Peritonitis Revealing an Incidental Neuroendocrine Tumor of the Appendix: A Rare Case Report and Review of the Literature". *Asian Journal of Research in Surgery* 7 (2):129-36. <https://journalajrs.com/index.php/AJRS/article/view/202>.

We report the case of a 57-year-old patient, a chronic smoker with 30 pack-year. The patient was admitted to our department as an emergency patient with perforated sigmoidal diverticulitis. Clinically, the patient presented a hypogastric pain and generalized abdominal tenderness on examination, the CT scan showed a pneumoperitoneum with multiple sigmoidal diverticula the surgical exploration revealed a perforated sigmoidal diverticulum with an inflamed appendix with a normal base.

In the light of this review of the literature, we would like to emphasize the importance of histological examination in the diagnosis of neuroendocrine tumors of the appendix, and to highlight the importance of intraoperative exploration, whatever the diagnosis.

*Keywords: Neuroendocrine tumor; adenoma; carcinoma; endocrine tumor.*

## 1. INTRODUCTION

Neuroendocrine tumors (NETs) of the appendix, also referred to as appendiceal endocrine tumors in recent literature, are rare, slowly progressive tumors, corresponding to the most common tumors of this organ [1]. They are detected with a prevalence of 0.3 to 0.9% in patients who had an appendectomy [2], representing approximately one to two cases per year per hospital, regardless of the surgical indication (annual incidence estimated at 1-2/100,000) [3]. A slight predominance in the female sex has been detected, perhaps reflecting a bias due to routine appendectomies performed during pelvic laparoscopy explorations. A first peak in incidence was noted in the 2nd decade for women and the 3rd for men, with the most aggressive tumors being found in the youngest patients. A second peak in incidence occurs in the 8th decade.

This neoplasia was initially described by Oberndorfer a century ago, under the term of carcinoid tumor [4], and considered to be tumors derived from intraepithelial enterochromaffin cells. Since then, several classifications have been proposed, taking into account histological architecture, neurotransmitter production (types A, B and C) and clinical aggressiveness [5].

The WHO has established a more precise classification, which does not depend on the immunohistochemistry of the tumor [6]. These tumors generally have an excellent prognosis; however, malignant forms do exist, associated with potentially fatal metastatic disease. Generally speaking, of all NETs of the digestive tract, those involving the appendix have the best 5-year survival rate (almost 100% compared with 50% for the esophagus).

## 2. CASE PRESENTATION

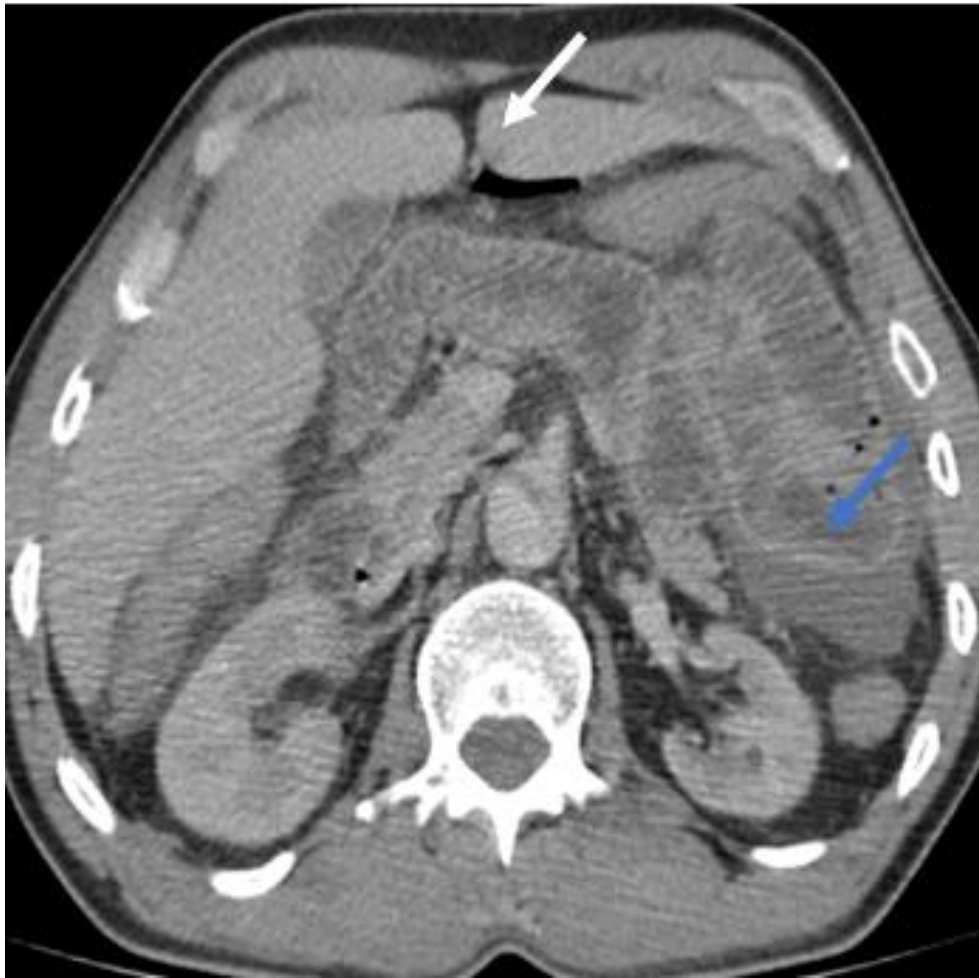
The patient was 57 years old, a chronic smoker with 30 pack-years. He was admitted to our department for a perforated sigmoid diverticulitis.

Clinically, the patient presented a generalized abdominal pain with a hypogastric origin and vomiting in a febrile state. Clinical examination revealed generalized abdominal tenderness. The thoracic-abdominal-pelvic CT scan showed small amount of pneumoperitoneum in the supramesocolic and submesocolic compartments and an abdominal effusion (Fig.1.) associated with multiple sigmoidal diverticula with one of them was perforated, and facing pneumoperitoneum bubbles (Fig. 2A and 2B).

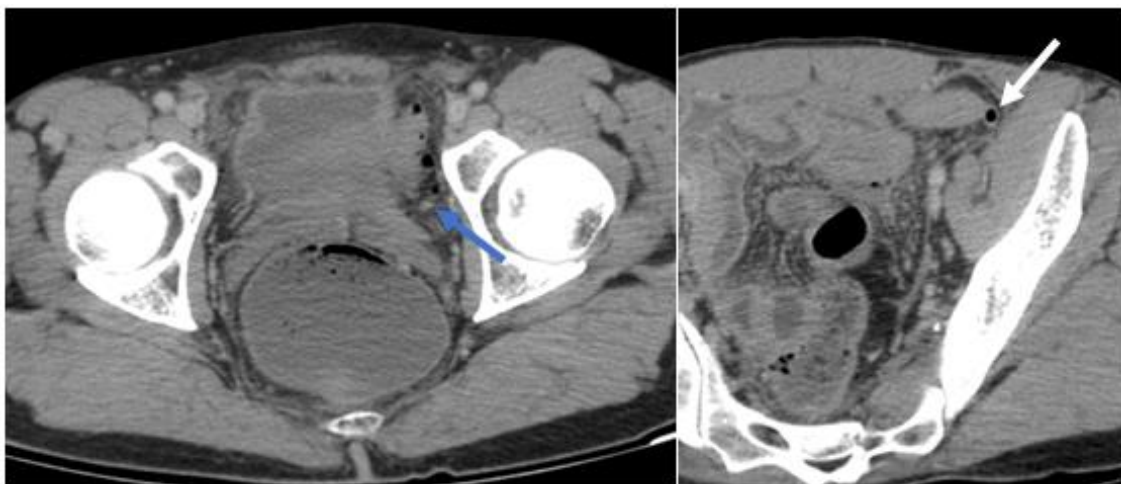
The biological checkup showed a normal hemoglobin at: 13.8 g/dl, hyperleukocytosis at 29180/mm<sup>3</sup> and normal platelets at 237000/mm<sup>3</sup>, Hydroelectrolyts were normal with Na<sup>+</sup>: 138 mEq/L and K<sup>+</sup>: 4.5 mEq/L, renal function was conserved with urea at 0.34 g/l, creatine: 6.4 mg/L.

Intraoperative exploration revealed a moderate peritoneal effusion of dirty liquid, false membranes throughout the abdominal cavity (Fig. 3.), especially at the submesocolic compartment, the presence of several sigmoidal diverticula, which one of them was perforated, the perforation was 0.5 cm, (none other diverticula was found in the rest of the colon) and a swollen appendix with a healthy base (Fig. 4).

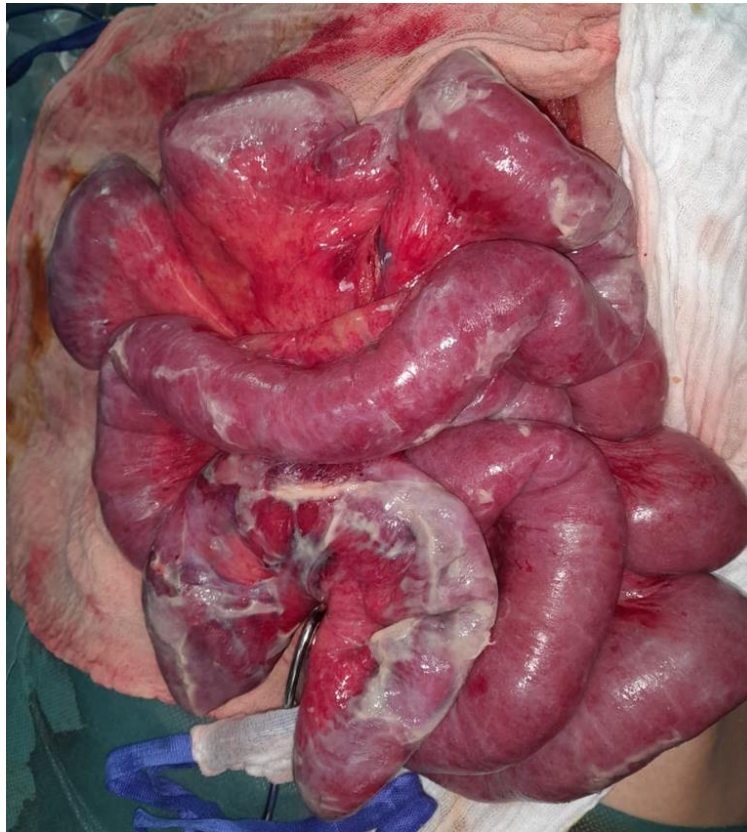
The procedure consisted of a segmental resection of the sigmoid removing several sigmoidal diverticula, one of which was perforated with realization of a Hartmann-type colostomy, retrograde appendectomy (Fig. 5) drainage of the CDS of Douglas using a Salem tube.



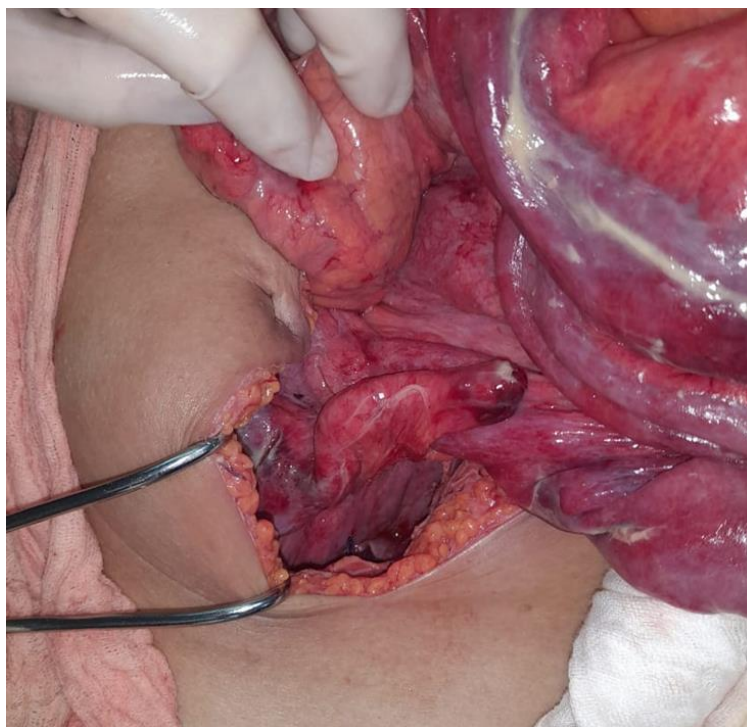
**Fig. 1.** Image of the CT scan showing the bubble of pneumoperitoneum (white arrow), associated with an abdominal effusion (blue arrow)



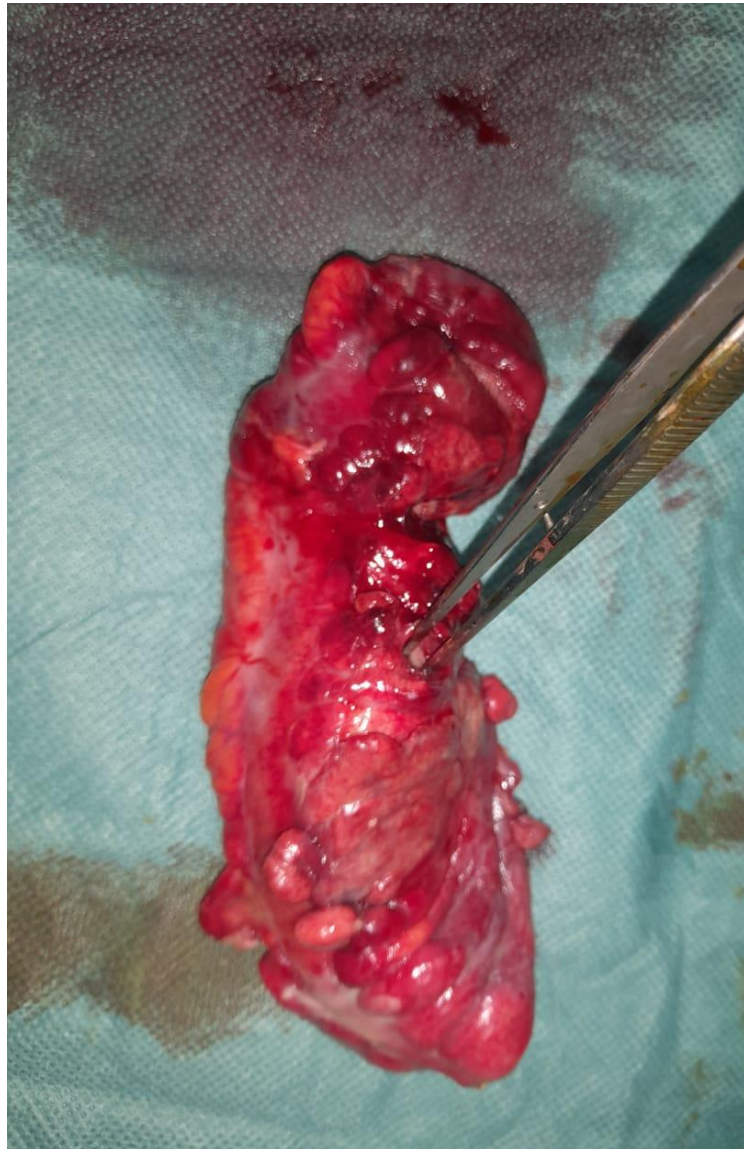
**Fig. 2. A and 2B:** CT scan image showing a multiple sigmoidal diverticula (white arrow), with one of them is perforated and facing pneumoperitoneum bubbles (blue arrow)



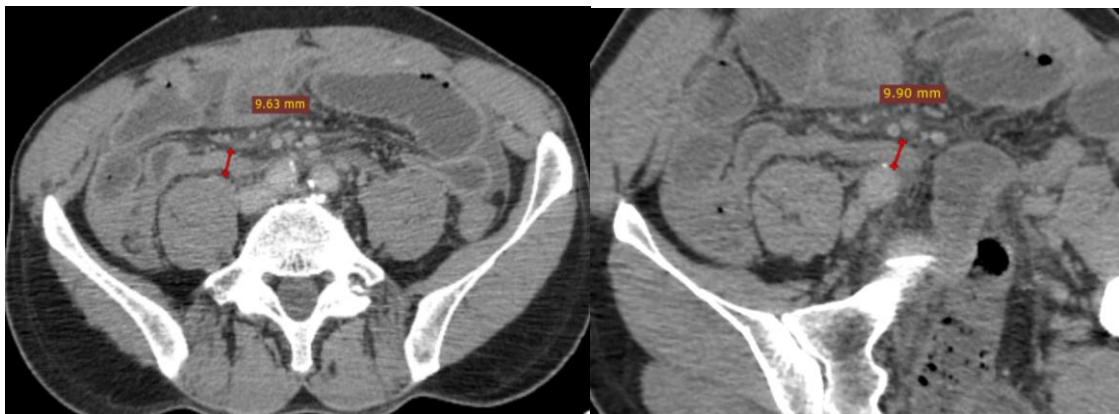**Fig. 3. Showing the small bowels with false membranes**



**Fig. 4. Showing the swollen appendix**



**Fig. 5. Showing the appendix after resection**



**Fig. 6. A and 6 B: CT scan pictures showing an increased appendiceal diameter**

A reinterpretation of the CT scan established an increased appendiceal diameter matching with the intraoperative finding.

### 3. RESULTS OF THE PATHOLOGICAL EXAMINATION

Sigmoidal resection specimen which morphological appearance was in favor of a sigmoidal diverticulum.

Appendix was measuring 7x1.1 cm, external surface covered with false membranes. On section, the wall shows hemorrhagic changes and the lumen is occupied by appendicolith. Histological examination of the samples taken showed that the appendix was the site of an invasive malignant tumor proliferation arranged in nests and made up of monotonous medium-sized cells with a rounded nucleus with finely stippled chromatin, rarely with an apparent nucleolus. Mitoses are found at a rate of 2 mitoses/2mm<sup>2</sup>. This profusion reaches the muscularis without exceeding it. No perinuclear sheathing or vascular emboli were seen.

In total: appendicular invasive malignant tumor proliferation, with a well-differentiated neuroendocrine appearance, coming into contact with the muscularis without protruding beyond it. Absence of vascular emboli and perineural sheathing.

The complementary immunohistochemical study showed a well-differentiated neuroendocrine carcinoid tumor of the appendix. Measuring 5x3mm, grade 1 (mitoses: 2 mitoses/2mm<sup>2</sup> and Ki-67 less than 3%). Contact with the muscularis without protruding beyond it. Absence of vascular emboli and perineural sheathing.

### 4. DISCUSSION

Neuroendocrine tumors of the digestive tract occur mainly in the small bowel (44.7%), followed by the rectum (19.6%), appendix (16.7%), colon (10.6%) and stomach (7.2%). [7] The annual incidence of neuroendocrine tumors of the appendix is estimated at 0.15 up to 0.6 per 100,000 people according to data from SEER (Surveillance Epidemiology and End Results) [8,9].

NETs of the appendix are usually asymptomatic [10]. Serial studies of accurate preoperative diagnosis by imaging are rare [11,12]. In the vast majority of cases, the diagnosis of appendiceal

neuroendocrine tumor is made incidentally on appendectomy specimens taken for acute appendicitis, as in the case of our patient, or for recurrent, chronic abdominal pain in the right iliac fossa [13]. The discovery of a tumor following a carcinoid syndrome is very rare (<1%) [14].

Preoperative diagnosis has a little value given that the majority of cases are discovered incidentally; current studies focus mainly on the early detection of recurrence in patients who have already undergone surgical treatment. In a large series of incidentally diagnosed appendicular neuroendocrine tumors involving 143 patients, the appendicular fundus was the predominant site of the tumor (82.4%) with a normal appendicular base in 95.9% of cases [15].

Histological diagnosis may sometimes be difficult with hematoxylin-eosin staining, especially in cases with the appearance of poorly differentiated adenocarcinoma, and therefore requires immunohistochemical study using anti-synaptophysin, anti-chromogranin A and anti-CD-56 antibodies [16, 17]. Lesions of acute appendicitis and peritoneal reaction can be observed in 66.1% and 45.1% respectively [15].

Plasma dosage of chromogranin A levels as a tumor marker contributes to the differential diagnosis of calciform cell neuroendocrine carcinoma and to the early detection of recurrence and long-term follow-up of metastatic disease [18].

CT scan, MRI and somatostatin receptor-based diagnostic positron emission tomography SSTR-PET scanning are recommended for tumors larger than 2 cm in diameter. Colonoscopy is recommended for the early detection of synchronous or metachronous tumors of the large intestine [18,19,20].

The diameter of appendiceal neuroendocrine tumors does not exceed 1 cm in almost 80% of cases. In 15% of cases, the diameter is between 1 and 2 cm, while in only 5% is it greater than 2 cm [21]. In the latter case, the potential for metastasis is considerable [22] and the 5-year survival rate is unfavorable [23]. The incidence of lymph node metastases is estimated at 30% [24] and only 1% for tumors with mesenteric invasion [25]. To this date, there have been no studies correlating the occurrence of lymph node metastases with invasion of the appendicular serosa [22].

Treatment depends to a great extent on the size of the tumor. Neuroendocrine tumors of the appendix less than 1 cm in diameter are treated by simple appendectomy, while neuroendocrine tumors between 1 and 2 cm in diameter are treated by simple appendectomy followed by periodic postoperative follow-up for 5 years. Right hemi-colectomy (within 3 months of appendectomy) should be reserved for patients with at least one of the following criteria: tumor size > 2 cm, tumor located at the base of the appendix, infiltration of the cecum, positive surgical resection margins, appendiceal mesenteric invasion, metastatic mesoappendiceal lymph node, presence of undifferentiated or poorly differentiated cells or presence of calciform cells [26,27,28].

## 5. CONCLUSION

Appendiceal neuroendocrine tumors are rare, usually asymptomatic, and their incidence is underestimated. Their prognosis is generally excellent, with a 5-year survival rate of 90-100% for all cases combined. Appendectomy alone is curative in a large percentage of cases. Additional radical surgery should be considered in certain circumstances, in particular for tumors larger than 2 cm, in the presence of positive local lymph nodes, or if the resection margins are affected.

## DISCLAIMER (ARTIFICIAL INTELLIGENCE)

Author(s) hereby declare that NO generative AI technologies such as Large Language Models (ChatGPT, COPILOT, etc) and text-to-image generators have been used during writing or editing of manuscripts.

## CONSENT

As per international standards or university standards, patient(s) written consent has been collected and preserved by the author(s).

## ETHICAL APPROVAL

Authors declare that the ethical approval has been exempted by my establishment

## COMPETING INTERESTS

Authors have declared that no competing interests exist.

## REFERENCES

1. Misdraji J. Neuroendocrine tumours of the appendix. *Curr Diag Pathol.* 2005;11:180-93.
2. Connor SJ, Hanna GB, Frizelle FA. Appendiceal tumors: Retrospective clinicopathologic analysis of appendiceal tumors for 7.970 appendectomies. *Dis Colon Rectum.* 1998;41:75-80.
3. Stinners B, Prothmund M. Neuroendocrine tumours (carcinoids) of the appendix. *Best Pract Res Clin Gas-troenterol.* 2005;19:729-738.
4. Obendorfer S. Karzinoide Tumoren des Dunndarms. *Frankfurt Z Pathol.* 1907;1:426.
5. Carr NJ, Sobin LH. Neuroendocrine tumours of the appendix. *Semin Diagn Pathol.* 2004;21:108-119.
6. O'Toole D, Scoazec JY. Tumeurs endocrines digesti-ves: pathogénie, diagnostic et classification. *Ann Pathol.* 2006;26:1555-1561.
7. Maggard MA, O'Connell JB and Ko CY: Updated population-based review of carcinoid tumors. *Ann Surg.* 2004;240:117-122.
8. Pape UF, Perren A, Niederle B, Gross D, Gress T, Costa F, Arnold R, Denecke T, Plöckinger U, Salazar R, Grossman A, and all other Barcelona Consensus Conference participants: ENETS Consensus Guideline for the Management of Patients with Neuroendocrine Neoplasms from the Jejunum-Ileum and the Appendix Including Goblet Cell Carcinomas. *Neuroendocrinology.* 2012;95:135-156.
9. KEUTGEN, Xavier M. et VAGHAIWALLA, Tanaz M. Surgical Evaluation of Appendiceal Neuroendocrine Tumors. *Neuroendocrine Tumors: Surgical Evaluation and Management.* 2021;191-206.
10. EĞİN, Seracettin, KAMALI, Gülçin, KAMALI, Sedat, et al. Neuroendocrine tumor of the appendix: Twelve years of results from a single institution. *Turkish Journal of Trauma & Emergency Surgery/Ulusal Travma ve Acil Cerrahi Dergisi.* 2019;25:2.
11. Pickhardt PJ, Levy AD, Rohrmann CA Jr, Kende AI. Primary neoplasms of the appendix: radiologic spectrum of disease with pathologic correlation. *Radiographics.* 2003;23:645-662.

12. Deeg KH, Reisig A, Seitz G. Sonographic diagnosis of a carcinoid tumour of the appendix in a 14-year-old boy. *Ultraschall Med.* 2003;24:120-122.
13. Modlin IM, Lye KD, Kidd M. A 5-decade analysis of 13,715 carcinoid tumors. *Cancer.* 2003;97: 934-959.
14. O'Donnell ME, Carson J, Garstin WI. Surgical treatment of malignant carcinoid tumours of the appendix. *Int J Clin Pract.* 2007;61:431-437.
15. Charfi S, et al. Tumeurs endocrines de l'appendice diagnostiquées fortuitement sur pièces d'appendicectomie: étude de 143 cas. *Annales de Pathologie.* 2011;31(5).Elsevier Masson.
16. Simon SR and Fox K: Neuroendocrine carcinoma of the colon. *J Clin Gastroenterol.* 1993;17: 304-307.
17. Caracappa D, Gullà N, Lombardo F, Burini G, Castellani E, Boselli C, Gemini A, Burattini MF, Covarelli P, Noya G. Incidental finding of carcinoid tumor on Meckel's diverticulum: case report and literature review, should prophylactic resection be recommended?. *World Journal of Surgical Oncology.* 2014;12: 1-6.
18. Plöckinger U, Couvelard A, Falconi M, Sundin A, Salazar Christ E, de Herder WW, Gross D, Knapp WH, Knigge UP, Kulke MH, Pape UF. Consensus guidelines for the management of patients with digestive neuroendocrine tumours: Well-differentiated tumour/carcinoma of the appendix and goblet cell carcinoma. *Neuroendocrinology.*2008;87:20-30.
19. MOHAMED, Amr, WU, Sulin, HAMID, Mohamed, et al. Management of appendix neuroendocrine neoplasms: insights on the current guidelines. *Cancers.* 2022 ;15(1): 295.
20. PAPE UF, NIEDERLE B, COSTA Frederico, et al. ENETS consensus guidelines for neuroendocrine neoplasms of the appendix (excluding goblet cell carcinomas). *Neuroendocrinology.* 2016; 103(2):144-152.
21. Debnath D, Rees J, Myint F. Are we missing diagnostic opportunities in cases of carcinoid tumours of the appendix? *Surgeon.* 2008;6:266-272.
22. GRINIATSOS, John; MICHAEL, Othon. Appendiceal neuroendocrine tumors: Recent insights and clinical implications. *World journal of gastrointestinal oncology.* 2010;2. Jg., Nr. 4, S. 192.
23. McGory ML, Maggard MA, Kang H, O'Connell JB, Ko CY. Malignancies of the appendix: Beyond case series reports. *Dis Colon Rectum.* 2005;48:2264-2271.
24. Stinner B, Rothmund M. Neuroendocrine tumours (carcinoids) of the appendix. *Best Pract Res Clin Gastroenterol.* 2005;19: 729-738.
25. Rossi G, Valli R, Bertolini F, Sighinol P, Losi L, Cavazza A, Rivasi F, Luppi G. Does mesoappendix infiltration predict a worse prognosis in incidental neuroendocrine tumors of the appendix? A clinicopathologic and immunohistochemical study of 15 cases. *Am J Clin Pathol.* 2003;120:706-711.
26. Landry CS, Woodall C, Scoggins CR, McMasters KM, Martin RC 2nd. Analysis of 900 appendiceal carcinoid tumors for a proposed predictive staging system. *Arch Surg.* 2008;143: 664-670. discussion 670.
27. Ramage JK, Davies AH, Ardill J, Bax N, Caplin M, Grossman A, Hawkins R, McNicol AM, Reed N, Sutton R, Thakker R, Aylwin S, Breen D, Britton K, Buchanan K, Corrie P, Gillams A, Lewington V, McCance D, Meeran K, Watkinson A. Guidelines for the management of gastroenteropancreatic neuroendocrine (including carcinoid) tumours. *Gut.* 2005; 54(4):iv1- iv16.
28. ABREU, Rui Pedro Neto da Silva. Appendiceal neuroendocrine tumors: Approach and treatment. *Journal of Coloproctology (Rio de Janeiro).* 2018;38 337-342.

© Copyright (2024): Author(s). The licensee is the journal publisher. This is an Open Access article distributed under the terms of the Creative Commons Attribution License (<http://creativecommons.org/licenses/by/4.0>), which permits unrestricted use, distribution, and reproduction in any medium, provided the original work is properly cited.

Peer-review history:

The peer review history for this paper can be accessed here:

<https://www.sdiarticle5.com/review-history/117817>