



## Phaeohyphomycosis in an Immunocompetent Host: Case Report and Literature Review

Fariba Binesh<sup>1</sup>, Jamshid Ayatollahi<sup>2</sup>, Nasim Behniafard<sup>3\*</sup>, Mansour Moghimi<sup>1</sup>  
and Maryam Vajihinejad<sup>1</sup>

<sup>1</sup>Department of Pathology, Shahid Sadoughi University of Medical Sciences, Yazd, Iran.

<sup>2</sup>Infectious Disease Research Center, Shahid Sadoughi University of Medical Sciences, Yazd, Iran.

<sup>3</sup>Otorhinolaryngology Research Center, Shahid Sadoughi University of Medical Sciences, Yazd, Iran.

### Authors' contributions

*This work was carried out in collaboration between all authors. Author FB designed the study, wrote the protocol and wrote the first draft of the manuscript. Authors JA, MM and MV managed the literature searches and analyses of the study performed the spectroscopy analysis. Author NB managed the experimental process and author MV identified the species of plant. All authors read and approved the final manuscript.*

### Article Information

DOI: 10.9734/BJMMR/2016/24583

#### Editor(s):

(1) Arun Chauhan, Department of Immunology and Microbiology, School of Medicine and Health, University of North Dakota, USA.

#### Reviewers:

(1) Mutlu Cayırlı, Mevki Military Hospital, Ankara, Turkey.

(2) Muhammed Jasim Abdul Jalal, Lakeshore Hospital and Research Centre, Ernakulam, Kerala, India.

(3) Abrao Rapoport, Sao Paulo University, Brazil.

(4) Anastasios J. Karayiannakis, Democritus University of Thrace, Greece.

Complete Peer review History: <http://sciencedomain.org/review-history/13779>

Case Study

Received 26<sup>th</sup> January 2016

Accepted 23<sup>rd</sup> February 2016

Published 21<sup>st</sup> March 2016

### ABSTRACT

**Aims:** Cutaneous phaeohyphomycosis is a rare disease. The term 'phaeohyphomycosis' is applied for various groups of dematiaceous fungal infections whose characteristics are pigmented hyphae production. In Iran, very few cases of phaeohyphomycosis have been reported.

**Presentation of Case:** Here a rare case of cutaneous phaeohyphomycosis has been reported in a 26 year- old immunocompetent woman with a 4- year history of an infection of the face and upper anterior aspect of the right leg. Histologic examination of the lesion illustrated features of phaeohyphomycosis.

**Discussion and Conclusion:** Physicians should retain a high clinical suspicion because phaeohyphomycosis may infect both immunocompromised and immunocompetent hosts.

\*Corresponding author: E-mail: [nbehniafard@gmail.com](mailto:nbehniafard@gmail.com);

**Keywords:** Immunocompetent; phaeohyphomycosis; cutaneous; histologic; immunocompromised; infection.

## 1. INTRODUCTION

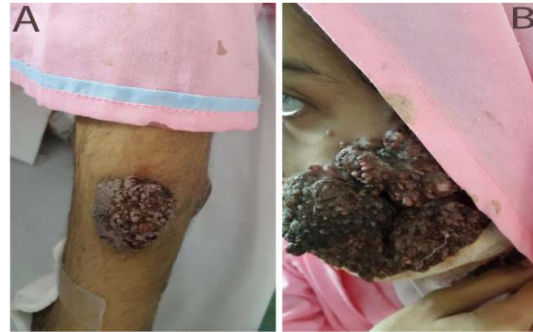Coined by Ajello in 1979, Phaeohyphomycosis is an infection caused by a darkly pigmented or 'dematiaceous' fungi that evolve their coloration from melanin in the cell walls [1] and are characterised by the presence of septate hyphae, yeasts or yeast-like forms. The term phaeo is derived from the Greek word phaios, which means gray and relegate to the color of these fungi in tissue and in culture medium. These fungi are typically found in the soil and are acquired through inhalation or penetrating trauma. This infection has been described in both immunocompetent and immunocompromised individuals [2]. In other word immunosuppression, is not an obligatory bet for the happening of phaeohyphomycosis. There are 5 clinical categories: (1): superficial; (2) cutaneous; (3) corneal; (4) subcutaneous; and (5) systemic, and cerebral. [3] Subcutaneous tissue is a popular site for phaeohyphomycosis and is universally thought to occur as a result of traumatic implantation or skin injury from the contaminated plants or soil [4]. More than 100 species and 60 genera of these fungi have been associated with cutaneous phaeohyphomycosis [5]. In recent decade many rare and new members of this group are rising as significant human pathogen. Although phaeohyphomycosis is an uncommon infection, trends toward an increasing outbreak have been noted especially in at-risk patients [6]. The diagnosis of phaeohyphomycosis depends upon demonstration of pigmented fungal structures by histopathology. Although this infection has been described worldwide, the incidence is higher in countries with tropical and subtropical climate. Clinically, the lesion begins as a papule, which then grows into a warty nodule or plaque at the site of implantation. Microscopically the skin shows hyperkeratosis and pseudoepitheliomatous hyperplasia and a diffuse chronic inflammatory infiltrate and granulomatous reaction. We herein present the histologic findings of a case of subcutaneous phaeohyphomycosis. This is the first reported case of phaeohyphomycosis from Yazd, Iran.

## 2. PRESENTATION OF CASE

A 26 years old female agricultural engineer from South Eastern of Iran and a low socioeconomic background was presented with painless a warty

nodule and plaque on her face of 4 years duration and right leg of 2 years duration. Fig. 1 showing these lesions. Lesions were chronically increased for the last several months.

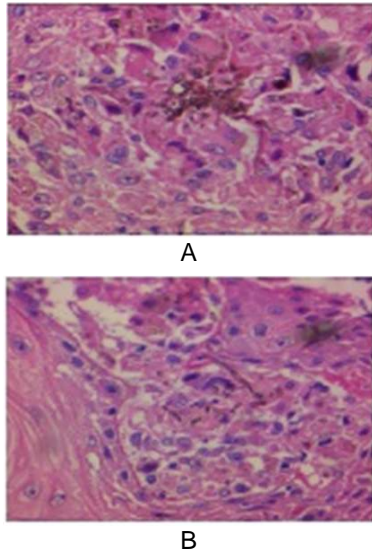
There was no history of systemic expression, pain or fever. She denied any considerable trauma. Physical examination revealed a 10x8 cm dark brown, diffuse and infiltrated plaque involving the anterior aspect of the right leg (Fig. 1A) that had a well-defined but irregular border with marked hyperplasia. In addition there was a large verrucous as well as nodular growth and elevated lesion 25x18 cm on her left face area with irregular border which involved both maxillary and mandibular areas (Fig. 1B).



**Fig. 1(A, B). Reveals huge warty nodules on her right leg and face**

On palpation, the lesions were soft and painless. Pressure of the lesions resulted in drainage of viscous yellow materials. No grains were visualized in the materials. There was no regional lymphadenopathy. Among routine investigations, hematologic and biochemical tests were unremarkable. Serological tests were found to be negative for and human immunodeficiency virus. Thereafter, the patient was evaluated regarding immunologic state which was within normal limits. An incisional biopsy sample measuring 2 x 1.8 x 0.7 cm was taken from the leg and sent for pathological evaluation. Sections showed skin tissue. The epidermis exhibited marked acanthosis. Nodular aggregates of epithelioid cells, multinucleated giant cells, neutrophils, and lymphocytes forming granulomas were seen in dermis and subcutaneous tissue. Within these nodules aggregates of pigmented hyphae were noted. These fungal elements consisted of short chains of brown-pigmented septate hyphae, and oval

yeast like cells. Pigmented hyphae were present within the cytoplasm of multinucleated giant cells. Fig. 2 (A, B) However, thick-walled sclerotic bodies were not identified. The final diagnosis was phaeohyphomycosis. The patient underwent partial surgical excision and received treatment with Itraconazole 200 mg BD. She responded partially to the surgical excision combined with antifungal therapy and discharged (for personal reasons). Unfortunately, the patient was lost for follow-up.



**Fig. 2A. Shows aggregates of pigmented hyphae (H&E x40), B: Reveals pigmented hyphae (H&E x40)**

### 3. DISCUSSION

During the last decades there has been an increment in the number of reported patients of phaeohyphomycosis. The increase may also be related to a heightened knowledge of this infection in humans and improved diagnostic methods. Phaeohyphomycosis may infect both immunocompromised and immunocompetent individuals with different clinical features, ranging from cutaneous infections to fulminant disseminated diseases. Predisposing agents include cancer, tissue transplantation, use of corticosteroids or other immunosuppressive drugs, and acquired immunodeficiency syndrome [7]. Our patient was an immunocompetent woman. Pooja Suri has reported a case of multiple brain abscesses caused by *C. bantiana* in an immune competent patient [8]. André Luiz Rossetto has explained a case of subcutaneous phaeohyphomycosis in an immunocompetent

patient [9]. A rare case of 25-year-old immunocompetent man with cerebral abscess has been described by Nandedkar S [10]. V. Arunagiri reported a 23 year old immunocompetent male with phaeohyphomycosis of the scalp [11]. José Napoleão Tavares Parente described two cases of subcutaneous phaeohyphomycosis in immunocompetent patients [12]. Phaeohyphomycosis affect men and women equally, and the highest incidence is between the third and fifth decades of life [13]. They are generally located in exposed areas such as the lower and upper limbs, however, Renan Minotto reported a 57-year-old woman with phaeohyphomycosis in the ungual apparatus [14]. Our case was a 26 years old woman and the lesions were on her face and her leg. The lesions usually remain localised as subcutaneous nodules. In some cases, the lesions may resemble the cauliflower-like lesions characteristic of chromoblastomycosis. Pseudoepitheliomatous hyperplasia, hyperkeratosis, parakeratosis, and acanthosis overlying the upper dermal granuloma are recognized in microscopic examination of phaeohyphomycosis. It was true about our case. The portal of entry is not well established. However, since these fungi exist as saprophytes in the environment, trauma has an important role in the pathogenesis of this disease. Sean M highlighted the role of trauma in the pathogenesis of subcutaneous phaeohyphomycosis. Their case, at age 10, had sustained traumatic implantation of wood splinters into the affected area during a tornado [3]. We believe that our patient has had traumatic implantation of fungal material from contaminated plants owing to her occupational exposure. To the best of our knowledge 6 cases of phaeohyphomycosis reported from Iran [15-20]. Iran has various climates and the disease has been reported from different regions. Phaeohyphomycosis should be considered in differential diagnosis of granulomatous inflammation presenting as cutaneous lesions. It should be distinguished from other specific pathologic conditions such as chromoblastomycosis and mycetoma, which are also caused by dematiaceous fungi. Chromoblastomycosis produces characteristic sclerotic bodies in tissue [21]. Mycetoma characterized by the presence of mycotic granules [21]. Since these fungi exist as saprophytes in the environment, cultures must be expound with care. Histopathology is an important tool in the diagnosis of phaeohyphomycosis. In other word the disease

is more of a histopathological than a clinical entity. Usually the diagnosis is made after excision with the histopathological examination as in this case. Specimens are frequently not cultured; thus, species identifications are not often made [22]. Surgical excision and antifungal therapy remain the standard remedies for cutaneous and subcutaneous phaeohyphomycosis. Surgical excision can eradicate the localized cutaneous phaeohyphomycosis. Itraconazole has been reported to be highly effective in phaeohyphomycotic infections, even in some resistant cases, but it is still unable to achieve a complete cure in some refractory cases [23]. In the present patient, complete surgical excision was supposed to be impractical, so she underwent partial surgical excision and received treatment with Itraconazole.

#### 4. CONCLUSION

In conclusion, cutaneous phaeohyphomycosis is a rare disease, causing ulceration and draining nodules not only in immunosuppressed patient but also in immunocompetent hosts. Skin is one of the organs most frequently affected by phaeohyphomycosis and histopathology plays a crucial role in diagnosis. Specimens should be handled carefully because of the known pathogenesis of these organisms in immunocompetent individuals.

#### CONSENT

It is not applicable.

#### ETHICAL APPROVAL

It is not applicable.

#### COMPETING INTERESTS

Authors have declared that no competing interests exist.

#### REFERENCES

1. Ajello L. The black yeasts as disease agents: Historical perspective. *Pan Am Health Organ Science Publ.* 1978;356:9-19.
2. Litchevski V, Goldschmidt A, Nass D, Rahav G, Cohen ZR. Cerebral phaeohyphomycosis in an immunocompetent patient: A case report

- and literature summary. *Clin Neurol Neurosurg.* 2014;124:179-81.
3. Hussey SM, Gander R, Southern P, Hoang MP. Subcutaneous phaeohyphomycosis caused by *Cladophialophora bantiana*. *Arch Pathol Lab Med.* 2005;129(6):794-7.
4. Desoubeaux G, Garcia D, Bailly E, Augereau O, Bacle G, De Muret A, et al. Subcutaneous phaeohyphomycosis due to *Phialemoniopsis ocularis* successfully treated by voriconazole. *Med Mycol Case Rep.* 2014;5:4-8.
5. Tay Y, Pan J, Lee S. Cutaneous phaeohyphomycosis in an immunocompromised host. *Hong Kong Journal of Dermatology & Venereology.* 2014;22(2):85-9.
6. Ben-Ami R, Lewis RE, Raad II, Kontoyiannis DP. Phaeohyphomycosis in a tertiary care cancer center. *Clinical Infectious Diseases.* 2009;48(8):1033-41.
7. CR CJ. Deep phaeohyphomycosis. In: William G. Merz RJH, editor. *Topley & Wilson's Microbiology & Microbial Infections Medical Mycology.* 10 ed. London. 2005;739-40.
8. Suri P, Chhina DK, Kaushal V, Kaushal RK, Singh J. Cerebral phaeohyphomycosis due to *Cladophialophora bantiana* - A case report and review of literature from India. *J Clin Diagn Res.* 2014;8(4):Dd01-5.
9. Rossetto AL, Dellatorre G, Persio RA, Romeiro JC, Cruz RC. Subcutaneous phaeohyphomycosis on the scrotum caused by *Exophiala jeanselmei*: Case report. *An Bras Dermatol.* 2010;(4)20:85-517.
10. Nandedkar S, Bajpai T, Bhatambare GS, Sakhi P. Cerebral phaeohyphomycosis: A rare case from central India. *Asian J Neurosurg.* 2015;10(2):142-4.
11. Arunagiri V. Subcutaneous phaeohyphomycosis of the scalp-a rare fungal infection treated by excision. *Sri Lanka Journal of Surgery.* 2015;32(4):30-1.
12. Parente JNT, Talhari C, Ginter-Hanselmayer G, Schettini APM, da Costa Eiras J, de Souza JVB, et al. Subcutaneous phaeohyphomycosis in immunocompetent patients: Two new cases caused by *Exophiala jeanselmei* and *Cladophialophora carrionii*. *Mycoses.* 2011;54(3):265-9.
13. Ramos-e-Silva M. *Fundamentos de dermatologia:* Atheneu; 2008.

14. Minotto R, Corte LD, Silva MV, Morais MR, Vettorato G. Phaeohyphomycosis of the ungual apparatus - Case report. *An Bras Dermatol*. 2014;89(4):649-51.
15. Basiri Jahromi S, Khaksar A, Irvani K. Phaeohyphomycosis of the sinuses and chest by *cladosporium bantianum*. *Medical Journal of the Islamic Republic of Iran*. 2002;16(1):55-8.
16. Didehdar M, Gokanian A, Sofian M, Mohammadi S, Mohammadi R, Aslani N, et al. First fatal cerebral phaeohyphomycosis due to *rhinocladiella mackenziei* in Iran, based on ITS rDNA. *J Mycol Med*. 2015;25(1):81-6.
17. Falahati M, Ghasemi Z, Zaini F, Farahyar S, Javad M, Najafzadeh MA, et al. The first case of onychomycosis due to *exophiala dermatitidis* in Iran: Molecular identification and antifungal susceptibility. *Bull Env Pharmacol Life Sci*. 2014;3(5):125-9.
18. Geramishoar M, Zomorodian K, Zaini F, Saadat F, Tarazooie B, Norouzi M, et al. First case of cerebral phaeohyphomycosis caused by *nattrassia mangiferae* in Iran. *Jpn J Infect Dis*. 2004;57(6):285-6.
19. Saberi H, Kashfi A, Hamidi S, Tabatabai SAF, Mansouri P. Cerebral phaeohyphomycosis masquerading as a parafalcian mass: Case report. *Surgical neurology*. 2003;60(4):354-9.
20. Najafzadeh MJ, Keisari MS, Farahyar S, Ganjbakhsh M, Ziaee M, Naseri AN, et al. Subcutaneous phaeohyphomycosis caused by sterile *Chaetomium* Spp. In Iran. *Jundishapur Journal of Microbiology*. 2013.
21. McGinnis MR. Chromoblastomycosis and phaeohyphomycosis: New concepts, diagnosis, and mycology. *Journal of the American Academy of Dermatology*. 1983;8(1):1-16.
22. Masini T, Riviera L, Cappricci E, Arienta C. Cerebral phaeohyphomycosis. *Clin Neuropathol*. 1985;4(6):246-9.
23. Zhang Y, Wang X, Li R, Kang Y, Shi X, Hagen F, et al. Facial subcutaneous phaeohyphomycosis caused by *Phialophora verrucosa*: Successful treatment with itraconazole and local resection. *JMM Case Reports*. 2015;2(1).

© 2016 Binesh et al.; This is an Open Access article distributed under the terms of the Creative Commons Attribution License (<http://creativecommons.org/licenses/by/4.0>), which permits unrestricted use, distribution, and reproduction in any medium, provided the original work is properly cited.

*Peer-review history:*

*The peer review history for this paper can be accessed here:*  
<http://sciencedomain.org/review-history/13779>