



# Treatment of Chronic and Severe Diabetes Mellitus with Ketoacidosis in a Four-Year-Old Intact Female American Pit Bull Terrier

**Matthew Benedict T. Calibo** <sup>a,b,++\*</sup>

<sup>a</sup> Department of Veterinary Clinical Sciences, College of Veterinary Medicine, University of the Philippines Los Baños, Laguna 4031, Philippines.

<sup>b</sup> Veterinary Teaching Hospital, College of Veterinary Medicine, University of the Philippines Diliman, Quezon City 1101, Philippines.

## **Author's contribution**

*The sole author designed, analysed, interpreted and prepared the manuscript.*

## **Article Information**

DOI: 10.9734/AJRAVS/2024/v7i2291

## **Open Peer Review History:**

This journal follows the Advanced Open Peer Review policy. Identity of the Reviewers, Editor(s) and additional Reviewers, peer review comments, different versions of the manuscript, comments of the editors, etc are available here: <https://www.sdiarticle5.com/review-history/116037>

**Case Report**

**Received: 17/02/2024**

**Accepted: 21/04/2024**

**Published: 23/04/2024**

## **ABSTRACT**

A four-year-old intact female American Pit Bull Terrier was brought to the hospital for unresolved weight loss, complete loss of fur, and persistent skin ulcers. Upon presentation, the patient showed severe dehydration, emaciation, and bilateral cataracts despite having reportedly good appetite and responsive behavior. Further examination and work-up diagnosed the patient with diabetic ketoacidosis – a complicated form of diabetes mellitus where insulin deficiency causes increased lipolysis and ketosis, resulting in ketonemia and metabolic acidosis. Multiple glucose curves and adjustments to insulin therapy led to the treatment of DKA and the successful management of diabetes. In the initial 5 months of treatment, the patient showed gradual but consistent improvement in clinical signs and quality of life. This case report shows the consequences and risks of having a severely diabetic canine patient remain undiagnosed and without appropriate

<sup>++DVM</sup>;

\*Corresponding author: E-mail: [mtcalibo@up.edu.ph](mailto:mtcalibo@up.edu.ph), [mattcalibo@gmail.com](mailto:mattcalibo@gmail.com);

insulin therapy. Highlighted through discussion and photos are the reversibility of clinical signs caused by the harmful effects of hyperglycemia, and the successful management of DKA and DM without hospital confinement.

**Keywords:** *Canine; pit bull terrier; emaciation; diabetes mellitus; diabetic ketoacidosis; insulin; hyperglycemia.*

## ABBREVIATIONS

**CBC** : complete blood count;  
**ALT** : alanine amino transferase;  
**Crea** : creatinine;  
**BGL** : blood glucose level;  
**DM** : diabetes mellitus;  
**DKA** : diabetic ketoacidosis;  
**BCS** : body condition score;  
**UTI** : urinary tract infection.

## 1. INTRODUCTION

Diabetes mellitus is a disease characterized by hyperglycemia resulting from insufficient insulin production or function [1]. Traditionally, type 1 diabetes mellitus (DM) or insulin-dependent diabetes (IDDM) develops from pancreatic beta cell destruction resulting in impaired insulin production and secretion. Type 2 DM or non-insulin-dependent diabetes (NIDDM) occurs when the body of the animal does not detect or respond to insulin appropriately, either due to a delayed response of insulin secretion or insulin resistance from receptor cell surfaces [2]. Almost all diabetic dogs have type 1 or IDDM, with very few exceptions, indicating that there is a general lack or absence of insulin in the circulation of a dog with DM [3,4,5].

The four classic signs of diabetes mellitus are weight loss, polyphagia, polyuria, and polydipsia (PUPD). The severity of these signs is directly related to the severity of hyperglycemia [6]. A dog with persistent fasting hyperglycemia with glucosuria and consistent clinical signs is diagnosed with diabetes. Normal blood glucose level (BGL) should not persistently exceed 100-250 mg/dL [7,8] or >8-11 mmol/L [9,10]. If left untreated, or the disease misdiagnosed, the prolonged and worsening hyperglycemia can progress to diabetic ketoacidosis.

Diabetes with ketoacidosis or diabetic ketoacidosis (DKA) is a severe and potentially life-threatening complication of DM wherein insulin deficiency causes an increase in lipolysis, resulting in ketonemia and metabolic acidosis [5,11]. Systemic signs of illness like lethargy and

anorexia ensue as progressive ketonemia and metabolic acidosis develop. The severity of systemic signs is directly affected by the severity of the metabolic acidosis and the nature of concurrent clinical disorders often present in DKA dogs [8].

The time from the onset of initial clinical signs of diabetes to the development of systemic signs due to DKA is unpredictable. It may be present at the time of initial diagnosis of diabetes mellitus, but it can also develop in a previously diagnosed diabetic dog that is already undergoing treatment [11]. Diagnosed diabetic dogs have been observed to continue normal existences for longer than 6 months without therapy. Once ketonemia, ketonuria, and metabolic acidosis begin to develop, severe illness typically occurs within a week [6] Not addressing DKA properly can lead to severe dehydration, prerenal azotemia, and emaciation.

Most diabetic dogs are over 5 years of age and intact females are at increased risk [9]. Based on the findings of a study by Hess et al. [12], the American Pit Bull Terrier is one of the dog breeds found to be at low risk for developing DM. Alternatively, Feldman and Nelson [6] state that any breed of dog or cat can develop DKA.

The mainstays of treatment of diabetic ketoacidosis are fluid therapy, correction of electrolyte imbalances, and insulin therapy. Fluid and electrolyte supplementation can start before a confirmed diagnosis as stabilization of the patient takes priority over insulin administration [7,11]. Once DKA is resolved and the patient is stable, the primary goals of insulin therapy for diabetic dogs are 1) resolution of all clinical signs 2) avoidance of insulin-induced hypoglycemia, and 3) return to ideal body condition while avoiding complications [9,11].

## 2. CASE PRESENTATION

### 2.1 Patient Information and Initial Visit

A four-year-old intact female American Pit Bull Terrier was presented in September 2020 to the

University of the Philippines Veterinary Teaching Hospital (UP-VTH) Diliman Station in Metro Manila for evaluation of the dog's long-standing poor and worsening condition. Although the owner observed a generally good appetite and normal stool consistency at home, the dog had severe emaciation, muscle wasting, and bilateral cataracts.

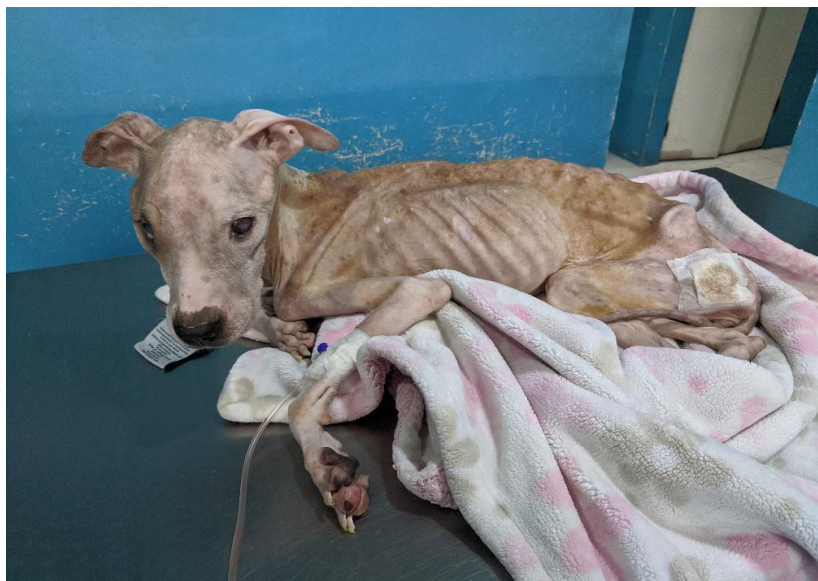The patient was acquired by her owner as a 2-month-old puppy and had no remarkable conditions or problems as a puppy. At 1 year of age, the dog began to get very skinny despite having a regular feeding routine and a healthy appetite. There proceeded to be a continuous decline in weight in the 3 succeeding years, though the patient showed no vomiting, only occasional wet stool, and had an active disposition at home. The dog had regularly updated vaccines, deworming, and heartworm prevention. The owner cited several prior veterinary consults that did not yield improvement for the dog's condition, despite varying treatments given or prescribed.

## 2.2 Clinical Findings

Upon initial presentation in the clinic, the dog had a body condition score of 1/9, showed minute amounts of muscle with no fat padding on the entire body, had skin sores on both lateral hips, and had bilateral thick white corneas with crusting around the eyes (Fig. 1).

Physical examination showed that the patient was alert and responsive but severely dehydrated and easily exhausted. The reflexes were normal, save for the lack of eyesight due to the thick bilateral cataracts. The rectal temperature was 37.6 Celsius, heart rate 52 beats per minute, respiratory rate 8 breaths per minute, mucous membranes pale pink in color and the dog weighed 6.8 kilograms. For comparison: according to the United Kennel Club [13], the desired body weight for a mature female American Pit Bull is between 13.6kg to 22.72 kg.

The abnormalities seen in the complete blood count were a low packed cell volume of 29.3% and thrombocytosis of 964,000 platelets/ $\mu$ L. The serum was moderately lipemic. Both total RBC and WBC counts were within the normal range. Alanine aminotransferase (ALT) and creatinine were both normal at 112 U/L and 0.3 mg/dL, respectively. Thyroid-stimulating hormone (TSH) was at <0.005 IU/mL, total triiodothyronine (T3) was 1.17 nmol/L, and total thyroxine (T4) was 44.34 nmol/L. Fasting blood glucose level (BGL) was extremely elevated at >649.08 mg/dL (>36.02 mmol/L) (Table 1). Urinalysis showed a urine specific gravity of less than 1.005, an acidic pH of 6.5, and was positive for both glucose and ketone bodies. Microscopic examination of urine revealed the presence of bacteria and white blood cells (Table 2). Other blood biochemistry tests and ultrasonography of the pancreas and liver were recommended but were declined by the owner.



**Fig. 1. The dog patient on Initial Presentation in the Veterinary Teaching Hospital. Severe emaciation and dehydration are apparent. Dry skin, the presence of pressure sores on both lateral hips, and bilateral cataracts were observed**

**Table 1. Complete blood count, ALT, creatinine, thyroid hormones, and blood glucose level test results of the dog patient. Performed on initial presentation to the UP-VTH. Reference values [14,15]**

Parameter	Patient	Normal Range
PCV (%)	29.3	33.6 – 58.7
RBC (x10 <sup>6</sup> /uL)	4.76	4.48 – 8.53
WBC (x10 <sup>3</sup> /uL)	13.3	4.0 – 17.6
PLT (x10 <sup>3</sup> /uL)	964	110 – 460
ALT (U/L)	112	14 – 151
Crea (mg/dL)	0.3	0.5 – 2.0
Total T4 (nmol/L)	44.34	15.0–50.0
Total T3 (nmol/L)	1.17	1.0–2.5
TSH (ng/mL)	<0.005	0–0.48
BGL (mg/dL)	649.08	80-120

Based on the results of the physical examination and the lab tests, a working clinical diagnosis of chronic diabetic ketoacidosis was made. The patient was given fluid therapy - using 0.9% NaCl - to address dehydration and then scheduled for insulin therapy. Hospital confinement was recommended but the owner could not afford this option due to the cost and the logistic difficulties during the COVID-19 pandemic. The owner and dog would return to the VTH for insulin therapy, with blood glucose curve plotting, over several days as an outpatient.

### 2.3 Therapeutic Intervention

The patient was placed on a continuous IV drip of lactated Ringer’s solution to address dehydration before insulin therapies were performed. The starting or base BGL of the dog pre-therapy was 592 mg/dL to >600 mg/dL. A glucose curve was done to observe hourly

changes in BGL and to attain the ideal dose to treat the patient’s diabetic ketoacidosis. Rapid, short-acting insulin with a concentration of 100 IU/mL was used for initial therapy - given IV. Whenever blood glucose would fall below 200 mg/dL, dextrose was added to the IV fluids to produce 5% dextrose solution. Crystalloid fluids were also infused with potassium chloride (KCl) at approximately 0.1 mEq/kg/h to address hypokalemia.

For day one of treatment, the patient was given gradually increasing doses of insulin while a glucose curve was done over 7 hours. The starting dose of insulin was 0.2 IU/kg and resulted in no significant changes in patient BGL. Increasing the dose of insulin by 0.6 IU/kg decreased the dog’s BGL to only 437 mg/dL at most. No adverse effects were observed throughout therapy. The hourly readings of BGL for day 1 are seen in Table 3.

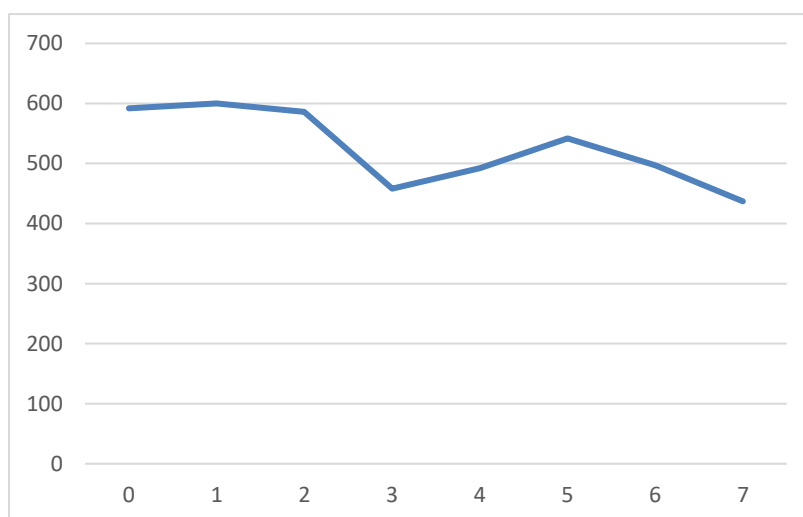
**Table 2. Urinalysis results of the dog patient. Performed on initial presentation to the UP-VTH. Reference values [14]**

Macroscopic examination		
Color	yellow	
Transparency	clear	
Chemical examination	Patient	Normal reference
Sp. Grav.	<1.005	1.001 – 1.070
pH	6.5	5.5 – 7.5
Leucocytes	negative	negative
Blood/hemoglobin	negative	negative
Nitrite	negative	negative
Ketones	2+	negative
Bilirubin	negative	negative
Urobilinogen	negative	negative
Protein	negative	negative
Glucose	4+	negative

Microscopic examination	Patient	Normal reference
WBC	>100/hpf	0
RBC	0-1/hpf	0
Mucus threads	Negative	Negative
Epithelial cells	Few	Negative - few
Casts	Negative	Negative
Crystals	Negative	Negative
Bacteria	Few	Negative

**Table 3. The first glucose curve – conducted on day 1 of treatment. Represented in a line chart below. Note: The maximum reading of the glucometer used was 600 mg/dL**

Hour	BGL (mg/dL)	Insulin administered (IU/kg)
0 – Fasting level	592	0.2
1	>600	
2	586	0.2
3	458	
4	492	0.2
5	542	
6	497	0.2
7	437	



**Graph 1. Day 1 glucose curve: BGL (mg/dL)**

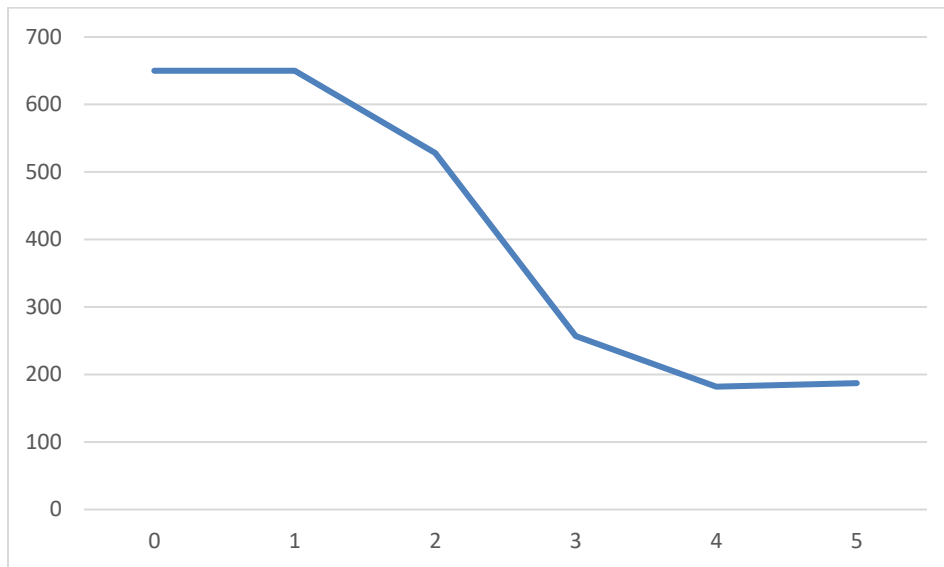
The second day of insulin therapy and performing a glucose curve was done for 5 hours. A starting dose of 0.8 IU/kg decreased BGL to 528 mg/dL. A stronger dose of insulin, 1.2 IU/kg, was added after 2 hours, which lowered patient BGL to 257 mg/dL. The succeeding dose of insulin given after an hour was 0.2 IU/kg, which decreased BGL further to 182 mg/dL. The hourly readings of BGL for day 2 are seen in Table 4. The only change in body condition observed during insulin therapy was erythema of the ear pinnae, during which body temperature remained normal at 38.0 °C. The owner was instructed to inject the equivalent of 2.2 IU/kg rapid, short-acting insulin

subcutaneously on the dog’s hips every 12 hours – 1 hour before her meals – as treatment for DKA and initial therapy for the diabetic condition.

The owner was advised to do daily monitoring of BGL using a glucometer and blood collected from a pricked ear vein. BGL would be checked 1 hour after insulin administration both before and after the daily meal. When possible, the owner would also inform the attending veterinarian of the dog’s home BGL readings. While being dosed subcutaneously with 2.2 IU/kg of rapid, short-acting insulin, the dog’s BGL would range between 224 mg/dL to 303 mg/dL in 1 to 2 hours post insulin administration.

**Table 4. The second glucose curve – conducted on day 2 of treatment. Represented in a line chart below. Note: The maximum reading of the glucometer used was 650 mg/dL**

Hour	BGL mg/dL	Insulin administered (IU/kg)
0 – Fasting level	>650	0.8
1	>650	
2	528	1.2
3	257	0.2
4	182	
5	187	



**Graph 2. Day 2 glucose curve: BGL (mg/dL)**

#### 2.4 Insulin Type and dose Adjustment

After approximately 1 month of using rapid, short-acting insulin, the owner shifted to using intermediate-acting insulin that reaches its peak effect in 2-4 hours; the owner was advised to adjust the timing of administration to 2-3 hours before the dog's meal. BGL measurement timing would be adjusted accordingly. After the insulin change, the dog's BGL was recorded at ranges between 100 – 170 mg/dL at 2-3 hours post insulin injection. There were 2 instances when the owner reported BGL at <60 mg/dL and the dog showed signs of shivering. As an adjustment, the owner was advised to decrease the succeeding doses to 1.0 IU/kg to prevent consistent hypoglycemia, to which the patient responded well. The average BGL of the patient one hour after her daily meal was 158 mg/dL during the next 4 months.

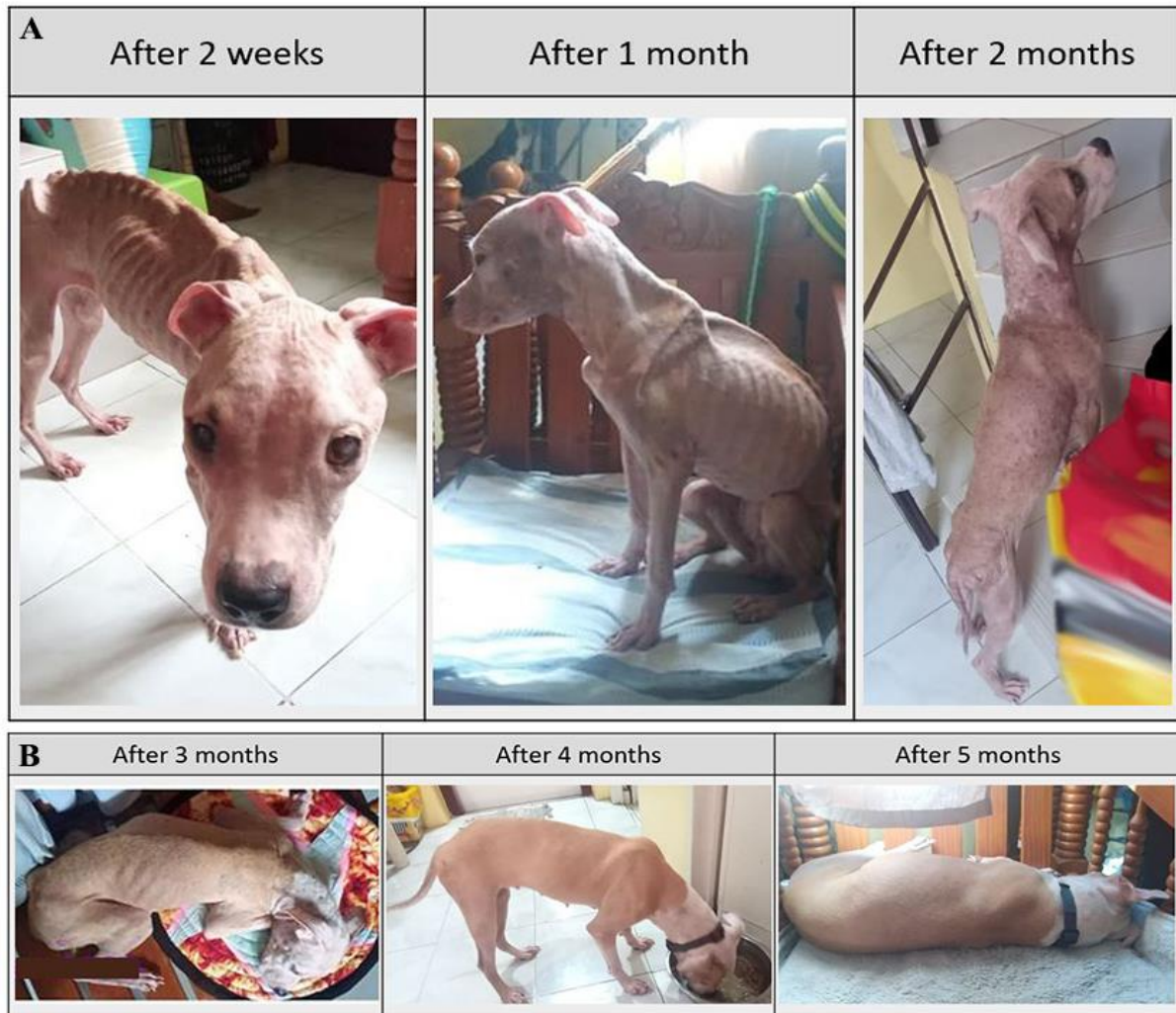#### 2.5 Follow-up and Outcomes

Photo updates of the patient during the 4 months after initial insulin therapy were sent monthly by

the owner which showed observable and consistent improvements in both BCS and overall appearance (Fig. 2A). The evident skin and bone form with protruding spine and ribs was gradually filled in with muscle and fat - first on the head, then axial skeleton, followed by the appendicular skeleton. After, the skin became less dry and in the third and fourth months, body fur began to regrow (Fig. 2B).

Five months after the initial DKA treatment, the patient was brought to the UP VTH for a check-up. The dog appeared generally healthy and presented with no clinical signs of disease or DM, except for bilateral cataracts still rendering the dog blind. The dog had good energy, a healthy pink mucous membrane, and a shiny coat of fur covering smooth skin (Fig. 3). BCS significantly improved to 4/9 with a body weight of 13.8kg. No more polydipsia was observed at home and the skin sores on both lateral hips had slowly healed about 4 months into insulin therapy. CBC results, creatinine, and ALT values were all within the normal range, with ALT decreasing to 27 IU/L from 112 IU/L.





**Fig. 2. A: Above – Progress of patient from 2 weeks to 2 months after start of insulin therapy  
B: Below – Progress of patient from 3 months to 5 months after start of insulin therapy**

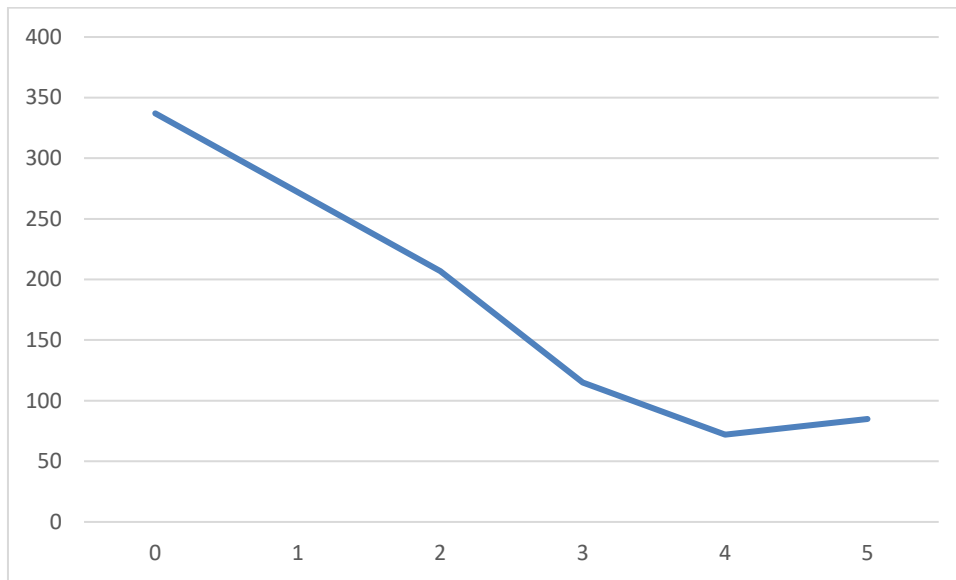
A glucose curve (Table 5) was repeated to assess changes in the dose efficacy of intermediate-acting insulin on the patient. 0.9% NaCl was used as IV fluids and the maintenance intermediate-acting insulin was administered SC to observe how it would lower BGL to within the normal range of 100-250 mg/dL [7,8]. Before this visit, the dog was kept off insulin for 24 hours, to compare its current fasting BGL with the initial presentation. This time, the fasting BGL of the patient was 337 mg/dL and a 1.0 IU/kg dose of insulin successfully decreased BGL to 115 mg/dL after 3 hours. After the 4th hour, the BGL decreased to 72 mg/dL before plateauing. Due to the owner's schedule constraints, the glucose curve had to be stopped early. To avoid daily lowering of BGL below 100 mg/dL, the insulin dose was reduced to 0.5 IU/kg. This dose was

used by the owner to give twice daily subcutaneous insulin injections with continued BGL monitoring. Weekly updates to the attending veterinarian reported that the dog's BGL was kept at normal range, with no signs of polyuria and polydipsia.

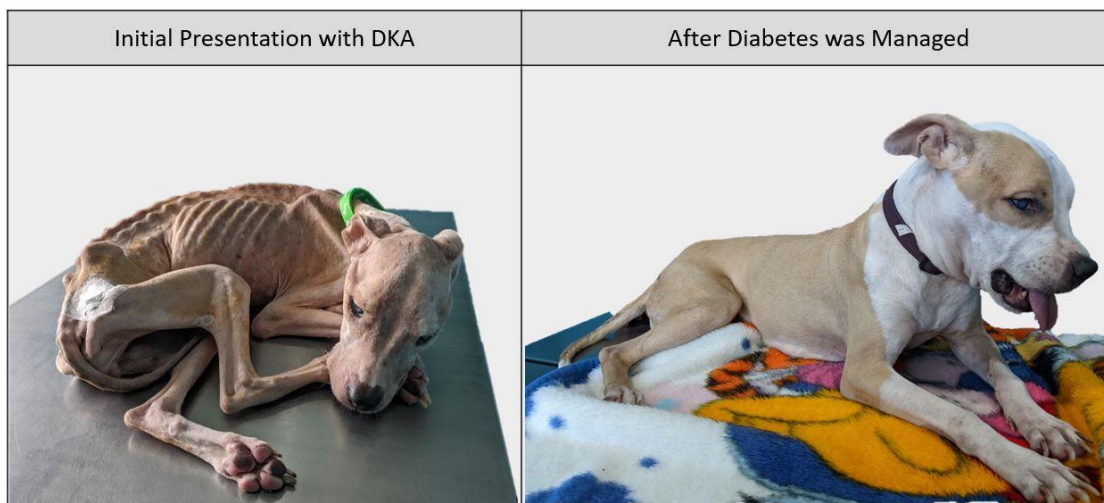After 72 weeks of consistently administering intermediate-acting insulin subcutaneously at home, the owner reported that the dog is bright, alert, and healthy with a BGL that is maintained within the normal range. The dog would still receive 0.5 IU/kg insulin daily through SC injections as maintenance, 2 hours before the daily meal. The comparison of the appearance of the dog on initial presentation and after DKA and DM resolution is shown in Fig. 3.

**Table 5. The third glucose curve – conducted 5 months after initial treatment. Represented in a line chart below**

Hour	BGL (mg/dL)	Insulin administered (IU/kg)
0 – Fasting level	337	1.0
1	272	
2	207	
3	115	
4	72	
5	85	



**Graph 3. Month 5 glucose curve: BGL (mg/dL)**



**Fig. 3. Comparison of the patient during the first presentation to the UP-VTH and during check-up after 5 months**

### 3. DISCUSSION

This report documents a remarkably severe and prolonged state of diabetic ketoacidosis (DKA) in

an adult intact female dog. The typical DM clinical signs – polyuria & polydipsia (PUPD), lethargy, depression, anorexia, and weakness – were all observed; however, grave



hyperglycemia, ketosis, and metabolic acidosis classified this case further as DKA.

The root cause of the patient's critical DKA condition was the chronic and undiagnosed diabetic condition. Though the patient was apparently healthy and with good body condition in the juvenile months of life, the onset of insulin deficiency after turning 1 year old resulted in sudden illness. Insulin is needed to enable the utilization of glucose for energy. Without insulin, lipolysis in adipose tissue, glycogenolysis in the liver, and protein degradation in muscles all increase. These result in depletion of fat stores, increased ketogenesis and liver enzyme activity, and diminished muscle mass, respectively [6,16,17]. Counter-regulatory hormones, such as glucagon, are also released in response to concurrent physiological stressors during DKA. This exacerbates glucose production, insulin resistance, and lipolysis [18]. These compounding processes resulted in the emaciated appearance of the dog upon presentation (Fig. 1).

The body's energy requirement prompted immediate adjustment for the lack of usable fuel. To provide substitute energy for metabolism, triglycerides in adipose tissue were broken down into free fatty acids (FFAs). FFAs in the bloodstream were oxidized by the liver into acetyl-coA, which were converted into ATP for metabolic use. Excess acetyl-coA in the bloodstream was diverted to create ketone bodies or ketones [7]. Ketones are crucial energy for the brain because the CNS cannot utilize FFAs for energy in substitute of glucose [19]. Ketosis then ensued as body tissues and brain cells became reliant on fat breakdown for energy [4]. Ketone bodies are acidic thus, their excessive production caused build-up in the circulation and development of metabolic acidosis [7]. The accumulation of ketones in the extracellular space eventually exceeded the filtering capability of the kidneys, resulting in the marked ketonuria observed through urinalysis.

While patient hyperglycemia was unresolved, persistent ketonuria, glucosuria, and osmotic diuresis caused grave dehydration of the patient [20]. Excessive loss of sodium, potassium, calcium, magnesium, and water led to hypovolemia, under perfusion of tissues, and the development of prerenal azotemia [8]. With compounding fluid losses through the gastrointestinal tract, this made it more difficult for the body to regain fluid homeostasis or

prevent a debilitating condition. Severe dehydration was clearly observed in the patient as the mucous membranes were pale white, both eyeballs were sunken, and the skin had poor turgor.

More classic signs of diabetes were observed in the eyes and on the skin of the patient. Bilateral cataracts developed due to the increased glucose levels in the aqueous humor and lens. Excess glucose here is converted to large concentrations of sorbitol, which is hygroscopic and pulls water into the lens. These lead to increased lens opacity and cataract formation [21,22]. Skin sores on both lateral hips were signs of diabetes-related wound development. Abnormally high blood glucose and an impaired circulatory system resulted in endotheliopathy, neuropathy, and immunopathy, making the patient prone to injuries, infection, and delayed healing [23].

Only one concurrent illness was observed in the patient - the UTI detected through urinalysis. UTI is classified as one of many stressful events or diseases that can trigger the shift from DM to DKA in a dog, according to Petroff and Greco [16]. Other possible catalysts include systemic infections, inflammatory disorders, and corticosteroid drug therapies. The UTI could have also occurred after the onset of DM or DKA, considering chronic hyperglycemia can alter the immune system and impair its function [24].

During the estimated 3 years that the diabetic condition persisted, the dog's routine was mostly unchanged. The dog was fed a diet of dry kibble mixed with boiled chicken liver and was kept confined within the owner's household. The dog did not experience any noteworthy bacterial or viral infections and did not develop any renal or hepatic disease, as supported by the blood tests. Thyroid hormone tests indicated neither hyper- nor hypothyroidism. All clinical signs were the effects of the cycle of hypo-insulinemia and hyperglycemia leading to ketoacidosis, which could have been prevented with a diagnosis of DM or DKA and appropriate insulin therapy.

### 3.1 Treatment

DKA treatment has two main aspects: fluid replacement and insulin therapy [7]. Fluids were given to immediately relieve dehydration, hypovolemia, and electrolyte imbalances in the patient. Correcting these through fluid administration will improve glomerular filtration in

the kidneys, significantly lower BGL, and decrease metabolic acidosis [14,7]. 0.9% sodium chloride (NaCl) was used for initial rehydration of the patient, but lactated Ringer's solution (LRS) was used during subsequent insulin administrations and glucose curves. Though 0.9% NaCl can resolve hyponatremia, the high chloride content risks hyperchloremic metabolic acidosis [7,11]. Using a balanced crystalloid with a buffer - LRS - is the optimal choice for quick resolution of acidosis. Insulin therapy should only be started after circulatory compromise and intravascular volume depletion are addressed; otherwise, there are increased risks of rapid changes in blood glucose, electrolyte depletion, and development of metabolic complications [11]. Insulin therapy can cause hypokalemia and hypoglycemia during DKA treatment. To counteract the potassium shift from intracellular storage to the bloodstream, the LRS was infused with KCL. To avoid hypoglycemia during insulin therapy, IV fluids were supplemented with 5% dextrose whenever BGL would drop below 200 mg/dL [7,11].

Insulin therapy for DKA has two primary goals: 1) reversal of ketogenesis and 2) reduction of blood glucose concentration. The normal BGL for canines is 100-250 mg/dL [7]. Controlling BG below the renal threshold (160 - 220 mg/dL) for as much of a 24 hr period as possible will improve clinical signs of both DM and DKA [9]. Determining the effective dose of insulin for the dog was the crucial next step in treatment.

Glucose curves were performed during hospital visits to determine an effective insulin dose both for initial DKA treatment and for long-term DM management. Performing a curve is done to discern whether the insulin is working consistently, how long it controls BGL, and whether the nadir of blood glucose is dangerously low [25]. Observing the changes in blood glucose concentration every hour via a glucose curve gave specific measurements of how quickly BGL would fluctuate. Obtaining a definitive glucose measurement is important for accuracy of insulin dosing and developing a therapeutic plan that ensures euglycemia and reduces risk of an overly rapid decrease in blood glucose [18].

The initial dose of insulin used was 0.2 IU/kg and was increased by 0.2 IU/kg per hour [5]. These incremental doses avoided rapid changes in glucose and electrolytes; however, were too low to elicit a sufficient decrease in BGL. The BGL

only decreased to an acceptable range (<250 mg/dL) at doses of 2.0-2.2 IU/kg [18] to which the dog exhibited no adverse reactions. Based on this patient and case findings, this reference dose is accurate for use as initial treatment of DKA - to quickly reverse hyperglycemia. It is expected that BGL will lessen to normal range before ketogenesis, and ketoacidosis are resolved.

Ketogenesis, ketoacidosis, and ketonemia resolved through insulin's effects on various body tissues, primarily by enabling cell utilization of glucose again as energy. This allowed the dog's body to regain normal metabolic function, build muscle, and improve skin. Insulin inhibits lipolysis, which decreases FFAs available for ketogenesis, and enhances peripheral ketone body metabolism. Insulin also promotes lipid synthesis and storage thereby reducing ketone body production in the liver.

The amount of insulin required to achieve euglycemia changed over time, as the dog's condition improved from DKA to uncomplicated DM. The initial dose of insulin needed for primary treatment of DKA and SC home injections, 2.0-2.2 IU/kg, sufficiently decreased the dog's BGL to normal range, without causing hypoglycemia. It was imperative to avoid hypoglycemia at home as BGL below 40-50 mg/dL can lead to altered behavior, ataxia, seizures, and even collapse [26]. The second dose of insulin, which was used for long-term management of uncomplicated DM, was 0.5-1.0 IU/kg given SC, and adequately maintained BGL at normal range. Insulin doses were halved whenever a BGL nadir would read <90 mg/dL, which signified risk for hypoglycemia if the current insulin dose was continued [27]. 0.5 IU/kg is still the dose that the owner uses as of writing this case report. Fleeman and Rand [9] report that the majority of uncomplicated diabetic dogs are stabilized on an insulin dose of approximately 0.5 IU/kg and few require doses larger than 1.0 IU/kg.

After DKA was resolved, the dog was shifted from short-acting insulin to intermediate-acting Neutral Protamine Hagedorn (NPH) (Humulin N<sup>®</sup>) insulin for long-term management of DM. Schaer and Schermerhorn [28] found that intermediate-acting NPH insulin is commonly used for dogs at a starting dose of 0.5 IU/kg SC every 12 hours. NPH is absorbed from SC injection after approximately 0.5 - 2 hours, with peak action at 2 - 10 hours, and total duration of action at 4 - 18 hours [28]. The owner would feed

the dog 2-3 hours post-insulin injection, which is well-timed given the onset and peak action of NPH. NPH insulin as daily therapy reduced BGL to averages between 89 to 170 mg/dL pre-meal and maintained it at 109 to 158 mg/dL post-meal. By keeping BGL below 180-200 mg/dL, NPH insulin was effective at managing DM and preventing glucosuria [9].

Several ideal conditions in DKA treatment could not be met for this case due to pandemic restrictions in 2020-2021, and the owner's financial capability. Treatment and stabilization of the DKA patient on initial presentation often involves a moderate to prolonged period of hospitalization, average of 5–6 days [11]. Instead, this dog was treated as an outpatient with the owner returning over several days to continue treatment, effectively prolonging patient rehydration. Several diagnostic imaging and blood tests - blood chemistry panel, electrolytes, and blood pH - were also not availed of. These tools and values would have aided in prompt diagnosis and focused electrolyte correction [7]. Lastly, glucose curves are ideally done after 4-7 days of insulin treatment. These last for 12-24 hours and are conducted at home where the dog is not in a stressful environment. The glucose curve here was done for 5-7 hours and in the hospital. The attending veterinarian needed the results of the glucose curve, the pre-insulin BGL and the minimum BGL, to evaluate if the doses of insulin could be increased without risk of inducing hypoglycemia [27].

It was recommended to the owner that the dog be spayed after DM was consistently managed and the dog was deemed fit for surgery. Fall et al. [29] report that diestrus and pregnancy are associated with increased progesterone concentrations and subsequent induction of growth hormone secretion by mammary tissue in dogs. These conditions can lead to the development of DM or contribute to diabetic instability of an intact bitch with previous DM. Gonadectomy is associated with decreased insulin resistance and, in some cases, remission of DM [30]. Though it is unclear if the onset of DM occurred during diestrus for this dog, an ovariohysterectomy would decrease the risks of possible DM complications.

#### **4. CONCLUSION**

This case showed the outstanding recovery of an intact adult female American Pit Bull Terrier patient from a complex form of diabetes mellitus - diabetic ketoacidosis or DKA. DKA occurred

because the diabetic condition of the dog was left unaddressed for 3 years, which required the body to break down all adipose, producing ketones to be used as substitute energy. A constant state of hyperglycemia and ketosis resulted in the dog's severe dehydration, blindness, and emaciation. Despite the severity of the condition, the use of appropriate fluid therapy and effective insulin doses allowed the dog's body to regain both acid-base balance and euglycemia. Diligent use of glucose curves helped ensure the accuracy of insulin dose adjustments during the different phases of both patient assessment and long-term treatment. The body condition and general responsiveness of the dog improved at a stable pace throughout insulin therapy while under home care. After 5 months of insulin therapy, the patient had fully recovered into an energetic, thickset dog with healthy skin and fur. By treating the root causes of the disease - lack of insulin and grave hyperglycemia - a favorable outcome for the patient was achieved. This report also exhibits that the monitoring and treatment of diabetic cases can be tailored to the individual case and patient, with promising results for all those involved.

#### **AVAILABILITY OF DATA AND MATERIALS**

This case report and the data here shall be made publicly available once published. The patient history and case findings used for this case report are available from the corresponding author upon request.

#### **ETHICS APPROVAL**

This report describes a case that was handled as one of the UP Veterinary Teaching Hospital's routine clinical caseloads; therefore, the institutional animal care and use committee (IACUC) or approval from an ethical governing body was not required. Owner consent was obtained for patient care in all aspects.

#### **COMPETING INTERESTS**

Author has declared that no competing interests exist.

#### **REFERENCES**

1. Rand JS. Diabetes Mellitus in Dogs and Cats. *Clinical Small Animal Internal Medicine*. 2020 Apr 30;93–102.

2. Banday M, Sameer A, Nissar S. Pathophysiology of diabetes: an Overview. Avicenna Journal of Medicine [Internet]. 2020 Oct 13;10(4):174–88. Available: <https://www.ncbi.nlm.nih.gov/pmc/articles/PMC7791288/>
3. Catchpole B, Ristic JM, Fleeman LM, Davison LJ. Canine diabetes mellitus: Can old dogs teach us new tricks? Diabetologia [Internet]. 2005 Sep 8;48(10):1948–56. Available: <https://link.springer.com/article/10.1007%2Fs00125-005-1921-1>
4. Hess R. Diseases of the Endocrine Pancreas (Islet Cells). In: Handbook of Small Animal Practice. Saunders Elsevier. 2005;471–2.
5. Tilley LP, Brainard BM, Sleeper MM, Smith FW. Diabetes Mellitus With Ketoacidosis. In Blackwell's Five-Minute Veterinary Consult: Canine and Feline. 7th ed. Wiley-Blackwell. 2021;395–6.
6. Feldman EC, Nelson RW. Canine diabetes mellitus. In: Canine and Feline Endocrinology and reproduction. 3rd ed. Philadelphia: W.B. Saunders Co. 2004; 486–538.
7. Thomovsky E. Fluid and electrolyte therapy in diabetic ketoacidosis. Veterinary Clinics of North America: Small Animal Practice. 2017 Mar;47(2):491–503. DOI: 10.1016/j.cvsm.2016.09.012
8. Nelson RW, Couto CG. Disorders of the endocrine pancreas. In: Small Animal Internal Medicine. 6th ed. St. Louis, MO: Mosby. 2020;808–45.
9. Fleeman L, Rand J. Canine diabetes mellitus. Clinical Endocrinology of Companion Animals. 2014 Jan 11;143–68. DOI: 10.1002/9781118997093.ch15
10. Gilor C, Niessen SJM, Furrow E, DiBartola SP. What's in a name? classification of diabetes mellitus in veterinary medicine and why it matters. Journal of Veterinary Internal Medicine. 2016 Jul;30(4): 927–40. DOI: 10.1111/jvim.14357
11. Boag A. Diabetic ketoacidosis and hyperglycaemic hyperosmolar syndrome. In: BSAVA Manual of Canine and Feline Endocrinology. Gloucester: British Small Animal Veterinary Association. 2023;243–6. DOI: 10.22233/9781910443866.23
12. Hess RS, Kass PH, Ward CR. Breed distribution of dogs with diabetes mellitus admitted to a tertiary care facility. Journal of the American Veterinary Medical Association. 2000 May 1;216(9):1414–7. DOI: 10.2460/javma.2000.216.1414
13. Breed Standards : American Pit Bull Terrier | United Kennel Club (UKC) [Internet]. 2017 [cited 2023 Sept 30]. Available: <https://www.ukcdogs.com/american-pit-bull-terrier>
14. Plumb DC. Plumb's Veterinary Drug Handbook. Stockholm, Wisconsin: Pharmavet Inc., Hoboken, Nj. 2018;1394–6.
15. Shiel RE, Sist M, Nachreiner RF, Ehrlich CP, Mooney CT. Assessment of Criteria Used by Veterinary Practitioners to Diagnose Hypothyroidism in Sighthounds and Investigation of Serum Thyroid Hormone Concentrations in Healthy Salukis. Journal of the American Veterinary Medical Association. 2010 Feb; 236(3):302–8. DOI: 10.2460/javma.236.3.302
16. Petroff BK, Greco DS. Endocrine Glands and Their Function. In: Cunningham's Textbook of Veterinary Physiology. 6th ed. Elsevier Health Sciences. 2020;394–420.
17. James HA, O'Neill BT, Nair KS. Insulin regulation of proteostasis and clinical implications. Cell Metabolism. 2017 Aug;26(2):310–23. doi:10.1016/j.cmet.2017.06.010
18. Koenig A. Complicated Diabetes Mellitus. In Textbook of Small Animal Emergency Medicine. 1st ed. Wiley-Blackwell. 2018;729–35.
19. Gal A, Odunayo A. Diabetes Ketoacidosis and Hyperosmolar Hyperglycemic Syndrome in Companion Animals. The Veterinary Clinics of North America. Small Animal Practice. 2023 May;53(3):531-550. DOI: 10.1016/j.cvsm.2023.01.005 PMID: 36898859.
20. Chiasson JL, Aris-Jilwan N, Bélanger R, Bertrand S, Beaugard H, Ekoé JM, Fournier H, & Havrankova J. Diagnosis and treatment of diabetic ketoacidosis and the hyperglycemic hyperosmolar state. CMAJ: Canadian Medical Association journal = Journal de l'Association Médicale Canadienne. 2003;168(7):859–866.
21. Basher AWP, Roberts SM. Ocular Manifestations of Diabetes Mellitus: Diabetic Cataracts in Dogs. Veterinary Clinics of North America: Small Animal Practice. 1995 May;25(3):661–76. Available: [https://doi.org/10.1016/s0195-5616\(95\)50061-0](https://doi.org/10.1016/s0195-5616(95)50061-0)

22. Stavinohova R. Surgical Treatment and post-operative Management of Diabetic Cataract in Dogs [Internet]. Veterinary Practice; 2023 [cited 2024 Jan 7]. Available:<https://www.veterinary-practice.com/article/treatment-and-management-canine-diabetic-cataract>.
23. Mieczkowski M, Mrozkiewicz-Rakowska B, Kowara M, Kleibert M, Czupryniak L. The Problem of Wound Healing in Diabetes—From Molecular Pathways to the Design of an Animal Model. International Journal of Molecular Sciences. 2022 Jul 19;23(14):7930. Available:<https://doi.org/10.3390/ijms23147930>
24. DeClue AE, Nickell J, Chang CH, Honaker A. Upregulation of Proinflammatory Cytokine Production in Response to Bacterial Pathogen-Associated Molecular Patterns in Dogs with Diabetes Mellitus Undergoing Insulin Therapy. Journal of Diabetes Science and Technology. 2012 May;6(3):496–502. DOI: 10.1177/193229681200600303
25. Davison L. Canine Diabetes Mellitus. British Small Animal Veterinary Association eBooks. 2023 Aug 1; 193–208. DOI: 10.22233/9781910443866.23
26. Idowu O, Heading K. Hypoglycemia in dogs: Causes, management, and diagnosis. Can Vet J. 2018;59(6):642- 9.
27. Fleeman LM, Rand JS. Evaluation of day-to-day Variability of Serial Blood Glucose Concentration Curves in Diabetic Dogs. Journal of the American Veterinary Medical Association. 2003 Feb;222(3): 317–21. DOI: 10.2460/javma.2003.222.317
28. Schaer M, Schermerhorn T. Fundamentals for Today's Insulin Therapy [Internet]. Today's Veterinary Practice; 2011 [cited 2024 Jan 7]. Available:<https://todaysveterinarypractice.com/pharmacology/fundamentals-for-todays-insulin-therapy>
29. Fall T, Hedhammar Å, Wallberg A, Fall N, Ahlgren KM, Hamlin HH, et al. Diabetes Mellitus in Elkhounds Is Associated with Diestrus and Pregnancy. Journal of Veterinary Internal Medicine. 2010 Nov;24(6):1322–8. Available:<https://doi.org/10.1111/j.1939-1676.2010.0630.x>
30. Fracassi F. Investigation and Management of Unstable Diabetics. In BSAVA Manual of Canine and Feline Endocrinology. British Small Animal Veterinary Association. 2023;227-42.

© Copyright (2024): Author(s). The licensee is the journal publisher. This is an Open Access article distributed under the terms of the Creative Commons Attribution License (<http://creativecommons.org/licenses/by/4.0>), which permits unrestricted use, distribution, and reproduction in any medium, provided the original work is properly cited.

*Peer-review history:*

*The peer review history for this paper can be accessed here:*  
<https://www.sdiarticle5.com/review-history/116037>