



## **Pneumoperitoneum Resulting from Severe Coronavirus Disease 2019 (COVID-19) Pneumonia**

**Chuah Jun Sen<sup>1,2\*</sup>, Lim Suat Yee<sup>3</sup>, Norsarah Shamsudin<sup>4</sup>, Tan Lin Jun<sup>5</sup>  
and Tan Jih Huei<sup>2</sup>**

<sup>1</sup>Department of General Surgery, Universiti Kebangsaan Malaysia Medical Centre, 56000 Cheras, Kuala Lumpur, Malaysia.

<sup>2</sup>Department of General Surgery, Hospital Sultanah Aminah, Ministry of Health Malaysia, Johor Bahru, Malaysia.

<sup>3</sup>Department of Respiratory Medicine, Hospital Sultanah Aminah, Ministry of Health Malaysia, Johor Bahru, Malaysia.

<sup>4</sup>Department of Radiology, Hospital Sultanah Aminah, Ministry of Health Malaysia, Johor Bahru, Malaysia.

<sup>5</sup>Department of Anaesthesia and Intensive Care, Hospital Sultanah Aminah, Ministry of Health Malaysia, Johor Bahru, Malaysia.

### **Authors' contributions**

*This work was carried out in collaboration among all authors. All authors read and approved the final manuscript.*

### **Article Information**

#### Editor(s):

(1) Dr. Asmaa Fathi Moustafa Hamouda, Jazan University, Saudi Arabia.

(2) Dr. Ramesh Gurunathan, Sunway Medical Center, Malaysia.

#### Reviewers:

(1) Deven Juneja, Max Super Speciality Hospital, India.

(2) Nazik Elmalaika Obaid Seid Ahmed Husain, Omdurman Islamic University, Sudan.

(3) Buleu Nicoleta-Florina, University of Medicine and Pharmacy "Victor Babes", Romania.

Complete Peer review History, details of the editor(s), Reviewers and additional Reviewers are available here:

<https://www.sdiarticle5.com/review-history/77606>

**Case Study**

**Received 06 November 2021**

**Accepted 06 December 2021**

**Published 09 December 2021**

### **ABSTRACT**

**Introduction:** Pneumoperitoneum is considered a surgical emergency, as it is highly associated with abdominal viscus perforation. Pulmonary origin of pneumoperitoneum secondary to invasive mechanical ventilation in severe COVID-19 pneumonia has been rarely reported in the existing literature.

**Presentation of Case:** A 62-year-old female was diagnosed with stage 5 COVID-19 pneumonia and was intubated due to respiratory distress. She subsequently developed pneumomediastinum, pneumothorax, subcutaneous emphysema and pneumoperitoneum a few days post-intubation.

However, there was no radiological evidence of abdominal viscus perforation from a computed tomography (CT) scan. Coupled with clinical findings and blood investigation, the patient was managed non-surgically with bilateral chest tubes and close monitoring of the intra-abdominal pressure. The pneumoperitoneum resolved a few days later. However, the patient continued to deteriorate throughout her stay at the ICU, due to concurrent nosocomial sepsis with kidney failure. Ultimately, the patient passed away on day 14 of her hospital stay.

**Discussion:** The management of pulmonary origin of pneumoperitoneum is mainly conservative with close observation of intra-abdominal pressure. Unnecessary non-therapeutic laparotomy of such a condition will potentially increase the mortality and morbidity of critically-ill COVID-19 patients.

**Conclusion:** Pneumoperitoneum resulting from severe COVID-19 pneumonia should be managed non-operatively, provided there is clear evidence of the absence of viscus perforation. A radiological examination, coupled with clinical findings and blood investigation, is crucial in establishing an accurate diagnosis.

*Keywords: Pneumoperitoneum; pneumomediastinum; mechanical ventilation; COVID-19.*

## 1. INTRODUCTION

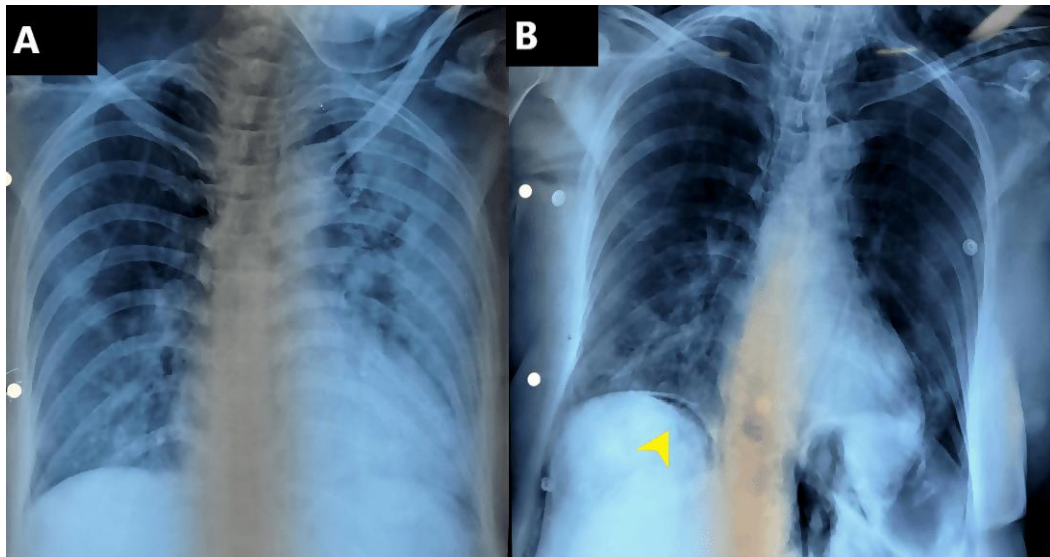
Pneumoperitoneum is an abnormal presence of air in the peritoneal cavity and is commonly treated as a surgical emergency associated with abdominal viscus perforation [1]. Patients with COVID-19 pneumonia and invasive mechanical ventilation are at higher risk of developing pneumomediastinum and pneumothorax [2,3]. Pneumomediastinum causing non-surgical aetiology of pneumoperitoneum in an invasive mechanical ventilated COVID-19 patient is a rare clinical entity in the literature. Establishing a correct diagnosis is crucial because the treatment for the underlying aetiology is different. Herein, we present such a case, which was managed conservatively with close observation of intraabdominal pressure. Non-therapeutic laparotomy will lead to higher rates of morbidity and mortality in a critically ill COVID-19 patient. Details of the case, including clinical presentation, imaging and management were discussed to alert surgeons and clinicians of such a rare condition.

## 2. PRESENTATION OF CASE

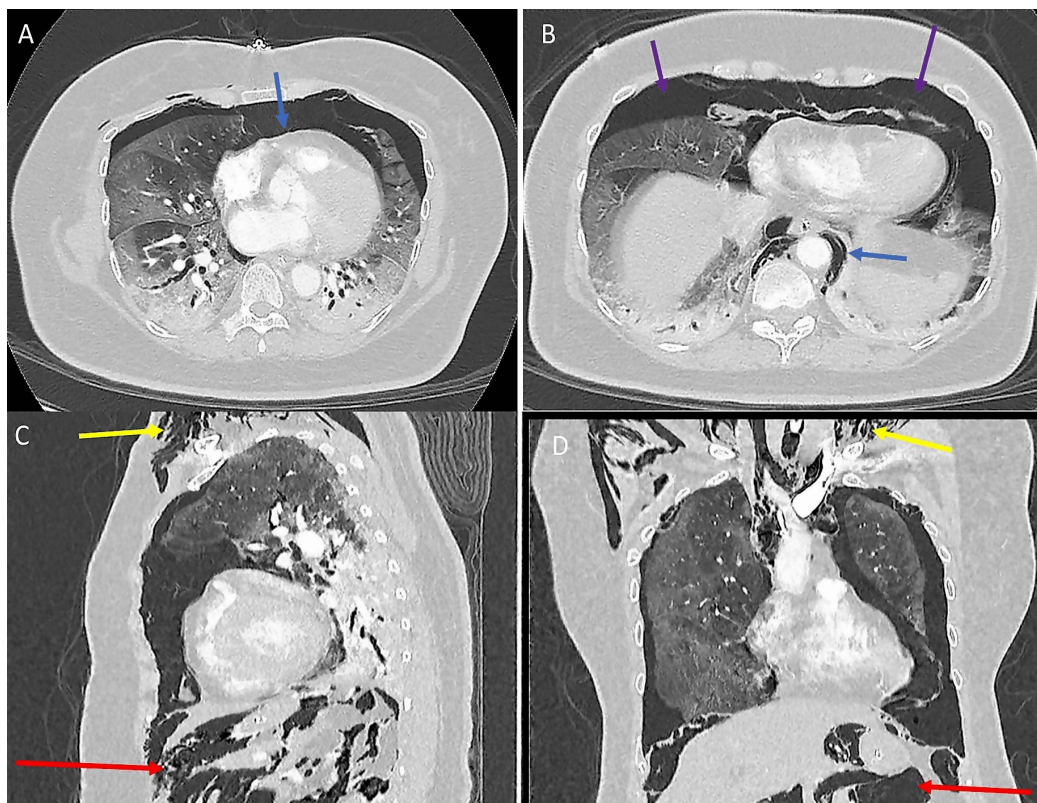
A 62-year-old female presented with shortness of breath associated with lethargy, poor appetite and cough for five days. Her co-morbid condition involved poorly-controlled diabetes mellitus, hypertension and dyslipidemia. On presentation, she appeared lethargic and tachypneic, with a respiratory rate of 32 breaths per minute and oxygen saturation (spO<sub>2</sub>) of 88-90% under ambient air. A chest X-ray showed bilateral ground-glass opacity, primarily affecting the periphery and basal regions of both lungs (Fig. 1). Blood work showed acute kidney failure with

raised C-reactive protein 124mg/L. A nasopharyngeal swab test for severe acute respiratory syndrome coronavirus 2 (SARS-CoV-2) was positive. Diagnosis of stage 5 coronavirus disease 2019 (COVID-19) pneumonia was established, and multi-modal treatments were initiated.

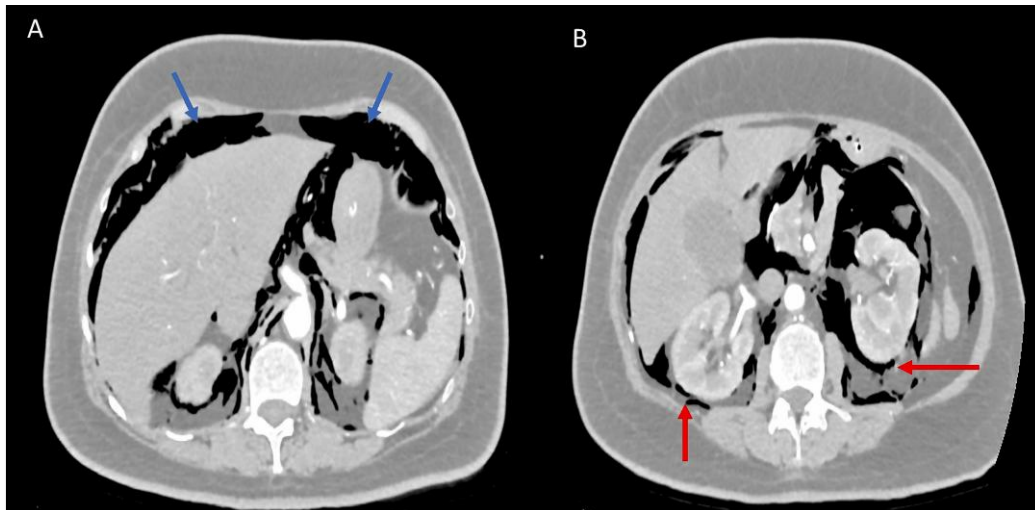
Subsequently, she was intubated and admitted to the intensive care unit (ICU). Over the next four days, the patient's respiratory support gradually increased and she had multiple desaturation episodes. She was nursed in the prone position and the ventilation setting was set to high (fraction of inspired oxygen 0.8 with positive end expiratory pressure 10) to maintain adequate oxygenation. She developed subcutaneous emphysema over the neck and chest. The presence of pneumomediastinum, pneumoperitoneum and subcutaneous emphysema was seen in a repeated chest X-ray (Fig. 1). Perforated abdominal viscus was suspected. Hence, an urgent computed tomography (CT) scan of the thorax and abdomen revealed diffuse ground glass densities in both lungs with pneumomediastinum, pneumothorax and concurrent pneumoperitoneum, without evidence of perforated viscus (Figs. 2, 3). Two chest tubes were inserted for bilateral pneumothorax. The patient was managed non-operatively, given the lack of clinical and radiological findings of visceral perforation. There was resolution of the pneumoperitoneum a few days later (Fig. 4). However, the patient continued to deteriorate throughout her stay at the ICU, due to concurrent nosocomial sepsis with kidney failure. Ultimately, the patient passed away on day 14 of her hospital stay.



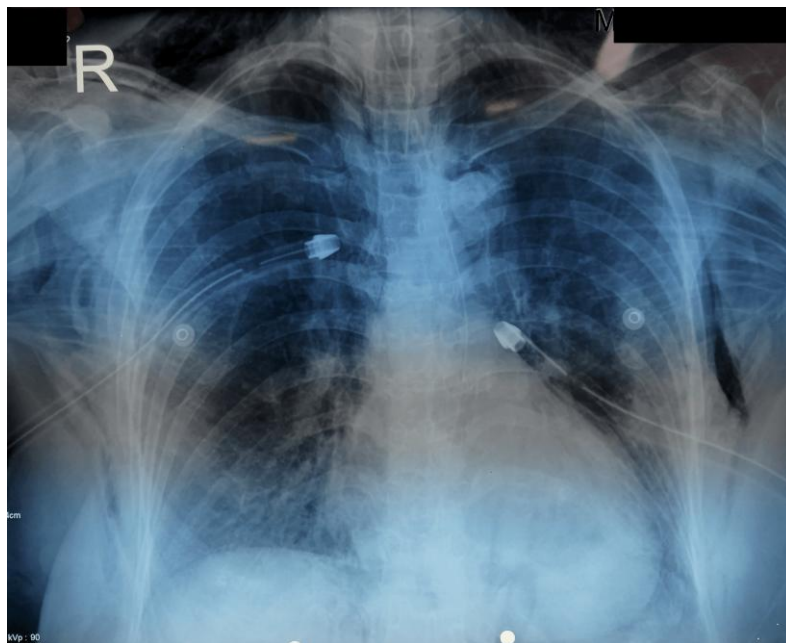
**Fig. 1. (A) Bilateral ground-glass opacity mainly affects both lungs periphery and basal region. (B) Subcutaneous emphysema at the left supraclavicular region with linear lucency outlining mediastinal and pericardium (pneumomediastinum and pneumopericardium) and air under the diaphragm (pneumoperitoneum –arrowhead)**



**Fig. 2. Axial images (A,B), sagittal reconstruction (C), and coronal reconstruction (D) of CT Thorax show extensive subcutaneous emphysema at the visualized lower neck (yellow arrow), extensive pneumomediastinum (blue arrow), bilateral pneumothorax with an extension of the air into the peritoneal cavity in keeping with massive pneumoperitoneum (red arrow) in the visualized upper abdomen. Diffuse ground-glass densities affect both lungs with dense consolidative changes at the dependent area of lungs (purple arrow)**



**Fig. 3. Axial images (A,B) at the upper abdomen level demonstrates extensive pneumomediastinum (blue arrows) involving visualized upper abdominal peritoneal cavity, also extending to involve retroperitoneal spaces (red arrows)**



**Fig. 4. Bilateral chest tubes inserted with the resolution of pneumoperitoneum**

### 3. DISCUSSION

Nearly 90% of pneumoperitoneum cases are associated with visceral perforation that requires emergency surgical intervention [1]. The remainder of cases are attributed to non-surgical aetiology such as mechanical ventilation, pneumothorax or cardiopulmonary resuscitation. The simultaneous presence of pneumomediastinum and pneumoperitoneum in a severe COVID-19 patient remained scarce in the literature.

COVID-19 potentially causes primary lung injury via diffuse alveolar damage, formation of intravascular microthrombi or acute fibrinous and organizing pneumonia [4]. A high risk of barotrauma was observed among COVID-19 patients on invasive mechanical ventilation, with resultant pneumothorax or pneumomediastinum, as in the case presented [2]. Such condition is associated with high mortality up to 60% [5]. Barotrauma leads to a rupture in the alveolar, which in turn causes an air leak in the pulmonary interstitium. The air leak will dissect along the



bronchovascular sheaths, towards the pulmonary hilum and mediastinum and cause pneumomediastinum, which is known as the Macklin Effect [6,7]. The free air is then leaking into the peritoneal cavity from the thoracic cavity.

Two mechanisms are used to explain how free air leaks into the peritoneal cavity. The first mechanism is thought due to communication between the thoracic and abdominal cavities by an undiagnosed diaphragmatic hernias such as posterolateral (Bochdalek) or parasternal (Morgagni) defects [8]. Another postulated mechanism is the passage of air from the mediastinum through the major diaphragmatic portals into the retroperitoneum, leaking into the peritoneal cavity [6]. The description latter is likely applied to our case, as evidenced by massive retroperitoneal free air (Fig. 3).

Accurate interpretation of such a condition is crucial and requires good correlation with radiological, clinical and blood investigation since non-therapeutic surgical intervention will incur higher morbidity and mortality on critically-ill severe COVID-19 patients. Our patient had radiographic evidence of the pneumoperitoneum, likely originating from the thorax, and there was no viscus perforation or intraabdominal collection. Clinically, the patient was hemodynamically stable and could tolerate enteral feeding well, with no rise in septic parameters. Therefore, we can conclude that there was no viscus perforation. The patient was managed conservatively with close monitoring for intra-abdominal pressure or abdominal compartment syndrome if the pneumoperitoneum worsened. In the event of abdominal compartment syndrome, immediate decompression via percutaneous drainage may be helpful [9]. The pneumoperitoneum resolved a few days later.

#### 4. CONCLUSION

Pneumomediastinum, pneumothorax and subcutaneous emphysema coupled with pneumoperitoneum are rare complications of COVID-19 pneumonia. Non-surgical aetiology of pneumoperitoneum can be managed non-operatively, provided there is clear evidence absence of viscus perforation. A radiological examination, coupled with clinical findings and blood investigation, are crucial in establishing an accurate diagnosis. Unnecessary laparotomy will further compromise the outcome of critically-ill COVID-19 patients.

#### CONSENT

Written informed consent was obtained from the patient's family for publication of this case report and accompanying images.

#### ETHICAL APPROVAL

The authors conformed to the provisions of the Declaration of Helsinki in 1995 (as revised in Brazil in 2013).

#### ACKNOWLEDGEMENTS

The authors thank all the efforts provided by the general surgery team and ICU team from Hospital Sultanah Aminah, Johor Bahru. The authors would like to express appreciation towards both intensivists, Dr Mahazir bin Kassim and Dr Seethal A/P Padmanathan for their efforts and hard works.

#### COMPETING INTERESTS

Authors have declared that no competing interests exist.

#### REFERENCES

1. Sharma M, Ojha P, Taweeseed PT, Ratnani I, Surani S. An Intriguing Case of Pneumoperitoneum In a Patient With COVID-19: Do All Pneumoperitoneum Cases Need Surgery? *Cureus*. 2020 Dec 25;12(12):e12279.
2. McGuinness G, Zhan C, Rosenberg N, Azour L, Wickstrom M, Mason DM et al. Increased Incidence of Barotrauma in Patients with COVID-19 on Invasive Mechanical Ventilation. *Radiology*. 2020 Nov;297(2):E252-E262.
3. Utomo SA, Notopuro F, Rosalina S. Massive emphysema subcutis, pneumothorax, pneumomediastinum and pneumoperitoneum as uncommon complication of covid-19 pneumonia, a rare case. *Radiology Case Reports*. 2021;16(8):2133-2138.
4. Polak SB, Van Gool IC, Cohen D, von der Thüsen JH, van Paassen J. A systematic review of pathological findings in COVID-19: a pathophysiological timeline and possible mechanisms of disease progression. *Mod Pathol*. 2020;33(11): 2128-2138.

5. Quincho-Lopez A, Quincho-Lopez DL, Hurtado-Medina FD. Case Report: Pneumothorax and Pneumomediastinum as Uncommon Complications of COVID-19 Pneumonia-Literature Review. Am J Trop Med Hyg. 2020;103(3):1170-1176.
6. Vidrio Duarte R, Vidrio Duarte E, Gutierrez Ochoa J, Gaviria Leiva MC, Pimentel-Hayashi JA. Pneumoperitoneum in a COVID-19 Patient Due to the Macklin Effect. Cureus. 2021;13(2):e13200.
7. Murayama S. Spontaneous pneumomediastinum and Macklin effect: Overview and appearance on computed tomography. WJR. 2014;6(11):850.  
DOI:10.4329/wjr.v6.i11.850
8. Lantsberg L, Rosenzweig V. Pneumomediastinum Causing Pneumoperitoneum. Chest. 1992;101(4):1176.
9. Fryman C, Mayo PH. A Patient With Coronavirus Disease 2019 Pneumonia and Sudden Decompensation While Receiving Mechanical Ventilatory Support. Chest. 2021;159(4):e281-e283.

© 2021 Sen et al.; This is an Open Access article distributed under the terms of the Creative Commons Attribution License (<http://creativecommons.org/licenses/by/4.0>), which permits unrestricted use, distribution, and reproduction in any medium, provided the original work is properly cited.

*Peer-review history:*

*The peer review history for this paper can be accessed here:*

<https://www.sdiarticle5.com/review-history/77606>