

Post-Varicella Disciform Keratitis: Case Report

Ozlem G. Sahin

The World Eye Center, Department of Uveitis, Ankara, Turkey.
Email: ozlem1158@yahoo.com, ozlem.gurses@dunyagoz.com

Received March 6th, 2012; revised April 16th, 2012; accepted May 10th, 2012

ABSTRACT

The purpose of this study is to report a rare condition of post-varicella disciform keratitis in a 4-year-old child. It is a prospective study of the follow-up of a 4-year-old girl who was diagnosed as post-varicella stromal disciform keratitis related to high serum antibody titers five months after the skin lesions. Rapid response to topical steroids, topical and oral antivirals have been observed in 6 weeks of treatment. There was no recurrence in the 6 months of follow-up. Total resolution of the disciform stromal keratitis in a short period of time was disclosed with an effective treatment of both topical and oral antivirals and topical steroids.

Keywords: Acyclovir; Disciform Keratitis; Trifluridine; Varicella Zoster

1. Introduction

Although varicella infections are common in Turkey related to the low varicella vaccination coverage, systemic and ocular complications are rare [1]. Corneal complications of varicella zoster virus include epithelial, stromal and disciform keratitis [2]. These complications are usually sight threatening, and they might lead to substantial visual disability [2]. We report a rare condition of post-varicella disciform keratitis in a 4-year-old child.

2. Case Report

A 4-year-old white female having a history of skin rash/vesicles 5 months ago presented with a haze on her right eye. Best corrected visual acuity (BCVA) of her right eye was 20/100, and her left eye was 20/20 (Snellen chart). The extraocular muscle functions and the pupillary light reactions were normal in both eyes. Her right cornea revealed a central localized area of disciform stromal edema without keratic precipitates (Figure 1). There was no cell and flare in the right anterior chamber. The right iris and pupil were normal, and the lens was clear. The slit-lamp examination of the left eye revealed no abnormalities. The fundus examinations of both eyes were normal. The intraocular pressure of the right eye was 18 and the left eye was 15 mmHg. Her specific serum IgM antibody against the varicella zoster virus (VZV) was 1.04 (<0.9 negative, >1.1 positive), and her specific serum IgG antibody against VZV was 2.94 (<0.6 negative, >0.9 positive). The culture and antibody titers to the other viruses including herpes simplex, rubella, ebstein barr and cytomegalovirus were negative. She was diagnosed as post-

varicella right disciform stromal keratitis. She was treated with frequent instillation of prednisolone acetate and trifluridine four times a day associated with oral acyclovir 20 mg/kg four times a day for 14 days. Her right cornea disclosed reduction of disciform stromal edema at the 2nd week of treatment (Figure 2). Prednisolone acetate was tapered and trifluridine were discontinued. Her treatment with slow reduction of prednisolone acetate was continued for 4 more weeks. The BCVA in the right eye improved to 20/20 at the 6th week of therapy, and her right cornea was clear without scarring, neovascularization, or lipid deposition (Figure 3). She is currently on the follow-up for possible recurrences, but no recurrence of keratitis was noted in the 6 months of follow-up.

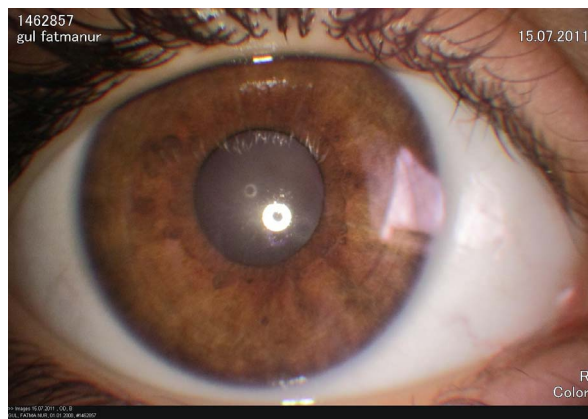


Figure 1. Color photo of the right eye at presentation. Note the central localized area of disciform stromal edema without keratic precipitates.

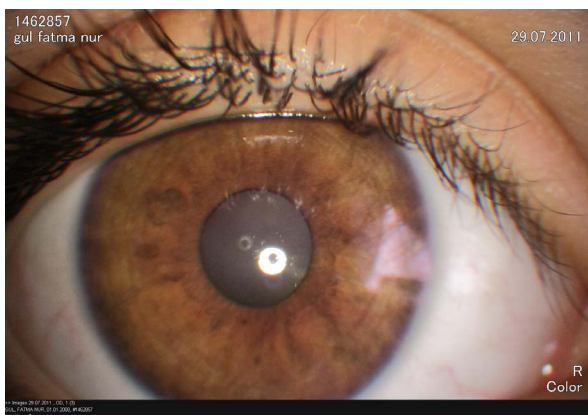

Figure 2. Color photo of the right eye at the 2nd week of treatment. Note the reduction of disciform stromal edema.

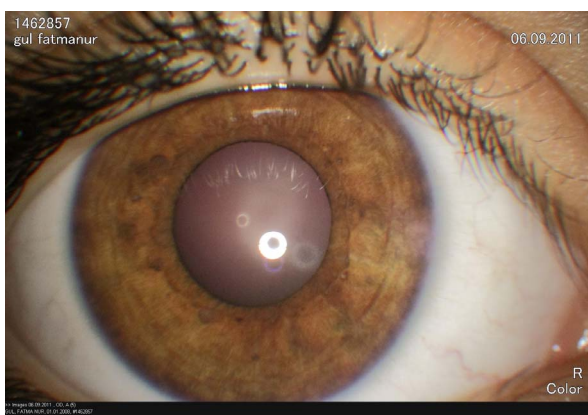


Figure 3. Color photo of the right eye at the 6th week of treatment. Note the clear cornea without scarring, neovascularization, or lipid deposition.

3. Discussion

VZV is a rare cause of disciform stromal keratitis that may occur and recur several weeks or months after the primary skin rash has resolved [3,4]. Delayed onset of keratitis represents a distinct category of VZV corneal complications [5]. Previously it was reported in 5 cases aged 4 - 26 years old within 1 - 10 weeks after onset of acute vesicular exanthem [3]. Our case was a 4-year-old female having a history of preceding skin eruption 5 months ago. Serologic analysis was reported helpful for the diagnosis of post-varicella keratitis [5]. Negative cultures, positive antibodies against VZV and negative antibodies against herpes simplex virus were important factors for serological diagnosis [5]. Our case revealed a positive serum specific IgG with a negative serum specific IgM titers for VZV indicating a delayed onset of VZV keratitis.

Antiviral therapy was considered an important intervention in clinical practice [6]. Oral acyclovir was an effective and useful drug of choice for the management of varicella in healthy children and adolescents [6]. The use of topical steroids alone might be harmful initially, and might increase the recurrence rate in the follow-up [7]. Trifluridine 1% solution was also effective for treating herpetic keratitis and seemed especially useful in difficult cases [8]. Our case showed a rapid resolution of the disciform stromal keratitis with frequent instillation of topical steroids and antivirals, and oral acyclovir. Based on this case and on a review of the literature, we believe that this delayed onset of keratitis represents a rare category of varicella corneal complications. However, it has a rapid and complete resolution with an effective treatment. We recommend oral acyclovir in conjunction with topical 1% trifluridine drops, and steroids for the therapy of post-varicella disciform keratitis.

REFERENCES

- [1] Z. Kurugol, O. Halicioglu, F. Koc, G. Koturoglu and S. Aksit, "Varicella Rates among Unvaccinated and One-Dose Vaccinated Healthy Children in İzmir, Turkey," *International Journal of Infectious Diseases*, Vol. 15, No. 7, 2011, pp. 475-480. [doi:10.1016/j.ijid.2011.03.016](https://doi.org/10.1016/j.ijid.2011.03.016)
- [2] S. Sanjay, P. Huang and R. Lavanya, "Herpes Zoster Ophthalmicus", *Current Treatment Options in Neurology*, Vol. 13, No. 1, 2011, pp. 79-91. [doi:10.1007/s11940-010-0098-1](https://doi.org/10.1007/s11940-010-0098-1)
- [3] K. R. Willhelmus, M. B. Hamill and D. B. Jones, "Varicella Disciform Stromal Keratitis," *American Journal of Ophthalmology*, Vol. 111, No. 5, 1991 pp. 575-580.
- [4] J. Martinez, F. Laquotte and L. Gauthier, "Post-Varicella Disciform Keratitis," *Journal Français D'Ophthalmologie*, Vol. 15, No. 11, 1991, pp. 597-600.
- [5] D. de Freitas, E. H. Sato, L. D. Kelly and D. Pavan-Langston, "Delayed Onset of Varicella Keratitis," *Cornea*, Vol. 11, No. 5, 1991, pp. 471-474. [doi:10.1097/00003226-199209000-00018](https://doi.org/10.1097/00003226-199209000-00018)
- [6] A. M. Arvin, "Antiviral Therapy for Varicella and Herpes Zoster," *Seminars in Pediatric Infectious Diseases*, Vol. 13, No. 1, 2002, pp. 12-21. [doi:10.1053/spid.2002.29753](https://doi.org/10.1053/spid.2002.29753)
- [7] J. McGill, "The Enigma of Herpes Stromal Disease," *British Journal of Ophthalmology*, Vol. 71, No. 2, 1987, pp. 118-125. [doi:10.1136/bjo.71.2.118](https://doi.org/10.1136/bjo.71.2.118)
- [8] A. A. Carmine, R. N. Brogden, R. C. Heel, T. M. Speight and G. S. Avery, "Trifluridine: A Review of Its Antiviral Activity and Therapeutic Use in the Topical Treatment of Viral Eye Infection," *Drugs*, Vol. 23, No. 5, 1982, pp. 329-353. [doi:10.2165/00003495-198223050-00001](https://doi.org/10.2165/00003495-198223050-00001)